

Zoonotic & Nonzoonotic Endoparasites of Rodents from Some Districts in Baghdad

Raad Hammodi Hasson*PhD

Abstract

A survey for zoonotic and nonzoonotic endoparasites of rodents carried out at some highly infested districts of Baghdad. A total of 186 rodents of three species was examined, comprising of 89 *R. norvegicus*, 62 *Rattus rattus* and 35 *Mus musculus*. Fourteen species belonging to twelve genera were identified. The most prevalent species of rodents was *R. norvegicus* in which zoonotic *H. diminuta* (24%), *H. nana* (10.7%) and *Cysticercus fasciolaris* (9%) were the most prevalent species of protozoan and helminth parasites respectively. Zoonotic protozoa *T. lewisi* and *Sarcocystis* sp. in *R. norvegicus* were most prevalent than *B. microti* in *R. rattus*. Nonzoonotic endoparasites *Vampirolepis* sp., *M. rodentium*, *S. obvelata*, *Trichuris* sp. and *T. musculi* were recorded with wide variation prevalence in the rodents species under study. New records of *B. microti*, new host for *T. lewisi* and *C. fasciolaris* (Strobilocercus) Hydatigena type larval infection of *Taenia* sp. of rodents species in Baghdad area under study.

Introduction

While little information is available on the distribution and incidence of most of the diseases with rodent reservoirs, many of them are known to be widespread and may have considerable public health importance in some of the foci in which they are found [12]; The frequency of disease transmission is facilitated by close - living of the three well known and wide spread commensal species *Rattus norvegicus* & *Rattus rattus* *Mus musculus* [11]. Rodents may transmit disease - causing organisms, particularly zoonotic endoparasites like

* College of Medicine\ University of Diyala

coetaneous & visceral leishmaniasis ; where in Iraq, the *Leishmania* sp. isolated from the viscera of the rat gave a pattern identical to that of *L. tropica* [4] ; *L.tropica* has been found in

one specimen of *R.rattus* [9] & *L. infantum* with *L. donovani* has been isolated from infected rats (*Rattus rattus*) in southern Saudi Arabia. [14] while only one serum of a *R.norvegicus* showed anti-*Leishmania* antibodies with 1:80 titer against *Leishmania* parasites with no parasite was found on impression smear slides of liver or spleen of this rat, in South West Iran [18] .

Concerning *Toxoplasma gondii* , Dubeya *et al* . (2006), During 2005, 238 rats (*Rattus norvegicus*) were trapped in Grenada, West Indies, and their sera along with tissue samples from their hearts and brains were examined for *T. gondii* infection;Antibodies to *T. gondii* were assayed by the modified agglutination test (MAT, titer 1:40 or higher); only 2 (0.8%) of 238 rats were found to be infected;

Brains and hearts of all rats were bio-assayed in mice ;*Toxoplasma gondii* was isolated from the brain and the heart of only one rat, which had a MAT titer of 1:320 ;Although in Egypt Rifaat *et al* . (1971) & also in Croatia Kuticici *et al* . (2005), recorded isolate of *T.gndii* when ingected rats & mice with brain tissue from outdoor caught rats & mice . The species most frequently implicated in human *babiosis* ;*Babesia microti* (Munich *B. microti* strain) isolated from *Mus musculus* in north-eastern Poland [32]; in Taiwan Of the 35 rats (8 *R. rattus* , 12 *R. coxinga*, and 15 *R. norvegicus* rats), only *R. coxinga* had evidence of babesial infection [31] ; Anderson *et al*. (1991) report the largest number of human babesiosis cases to date have been contracted on the mainland United States where the isolation of *B. microti* from humans living in southeastern Connecticut and also the isolation of *B. microti* from a mouse captured in Connecticut as early as 1988 . A human case of *T. lewisi* in a child in india reported by Johnson (1933) , and on a case of sick infant from Thailand Nachai *etal*. 2007 was concluded that the infant was infected with a *T. lewisi*-like (*Herpetosoma*) species , hereby Shrivastava& Shrivastara (1974) mentioned about two human cases of *trypanosma sp.*in india ; Pinto *etal*. (2006) mentioned about first report of *T. lewisi* and *T. rangeli* from the rat *R. rattus* in Ecuador ; this view shed light on the neglected public health of this parasite . In Arbil , Iraq, *Trypanosoma lewisi* was found in 7 (7.07%) of 99 *R. rattus* and in 5 (17.86%) of 29 *R. norvegicus*, while *Trypanosoma musculi* was found in 4 (3.80%) of 105 *M.*

musculus and this is the first record of this trypanosome from rodents in Iraq [21] . In addition, rodents can harbor many different protozoan and helminthes endoparasites of public health ; a rare reports of human infections with, *Sarcocystis* sp. [7] and *Cysticercus fasciolaris* [33] , Hydatiosis and numerous papers on Hymnoleiasis .

However, little had been documented on the aspect of rodent parasites of both zoonotic and nonzoonotic in the literatures Iraq with only a few notable investigations in the past on such as Senekji (1940) ; Almorshidi 2001; Al-Awsy (2005); Jawdat and Mahmoud (1980); Al-Barwari *et al.* (1987) and Mahmoud (1974) who reported in rats *Giardia muris* 16.2% , *Chilomastix bennettii* 6.3% , *Trichostrongylus axei* 56.8%, *Entamoeba histolytica* 8.1% , *E.coli* 10.8% , *Eimeria* sp 4.5% , *H.nana* 8.1% , *H. diminuta* 13.5%, *Trichuris muris* 2.7% , *Aspicularis tetraptera* 2.7% , *Syphacia obvelata* 6.3% , *Gongylonema neoplasticum* 1.8%, *Streptopharagus kuntzi* 8.1% *Pterygodermatitis witnbergi* 3.6 % , *Moniliformis moniliformis* 5.4% ; while in mice had recorded 12 species of intestinal parasites *Giardia muris* 6.9% , *Chilomastix bennettii* 11%, *Trichostrongylus axei* 42.5 % , *Entamoeba histolytica* 19.2 % , *E.coli* 10.9% , *Eimeria* sp 27.4% , *H.nana* 8.2 % , *H. diminuta* 6.9% , *Hydatigera taeniaformis* 16.4 % , *Syphacia obvelata* 11% , *Aspicularis tetraptera* 5.5% , *Trichuris muris* 24.7% .

Molan *et al.* (1988) recorded from 9 different localities in Arbil area , Iraq ; from 232 rodents trapped , 147(63.4%) were infected with Helminths . Among 105 mice 77 (73.3%) were infected with *Hymenolepis nana* , in 15 *H. diminuta* , in 7 Metacestodes of *Taenia taeniaformis* , in 9 *Aspicularis tetraptera* , in 20 *Syphacia obvelata* and *Trichuris muris* in 8 .Thirty four (34) of 99 rats were infected with cestode , including *H. diminuta* in 31 and *Mathevotaenia rodentium* in 3 . eight (8) of 28 *Rattus norvegicus* were infected with *A. tetraptera*.

Regarding to what has been said hitherto, we studied in present survey the internal parasites of rodents in five districts in Baghdad known with high density of rodents and rat-man proximity as recorded by Hasson (2009 , same author) . An important aim was given to find Helminths and tissue protozoan parasites with particular reference to those parasites represent a health threat to man [13].

Materials and Methods

During 1990-1994, 186 rodents collected in five residential district blocks with high density prevalent rodents such as Aljamhuiya 38.60%, Abunoas 45%, Karada 32.80%, Kelani 52.2% & Saadon 50%; traps were collected and transported to Baghdad endemic department. Rodents were trapped alive; before killing, caught rodents were anesthetized in plastic bags with chloroform to control animal and for combing by brush to collect ectoparasites which preserved by 70% alcohol for further studies; then animals were dissected. A slide smears were prepared from the blood (thick and thin) and internal organs, including spleen, heart, brain, muscles and liver (impression smears). The smears were prepared from all animals and were preserved and stained with standard Giemsa stain and examined microscopically for the amastigote form of *Leishmania* and for cysts of *Toxoplasma gondii*; fecal & alimentary tract contents evacuated and examined directly by dissecting microscope; samples of eggs & Helminths preserved by 10% formalin; in addition to the centrifugal flotation and sedimentation techniques were used according to Beaver and JUNG (1985) [8].

In this technique 2 grams of fecal sample and 30 ml of saturated NaCl (aq) solution were mixed to prepare fecal emulsion. The emulsion then strained through a tea strainer into 15 ml conical centrifuge-tube on which top a cover slip was placed. Centrifugation then done for 10 minutes at 1500 (r.p.m.), after which the cover slips were removed and placed on clean microscope slides and examined at X_{10} magnification level. Sometimes it was necessary to confirm the identification by using the magnification level X_{40} to visualize the internal structures of eggs or oocysts.

Sedimentation technique, on the other hand, was used to detect the trematoda eggs, an approximate 2gms of feces were weighed and put in a container with 40 ml of tap water. The mixture was stirred using a fork and then the fecal suspension was filtered through a tea strainer into another container. The filtrate was then poured into a test tube and allowed to stand for five minutes. The supernatant was then decanted carefully and the sediment was then re-suspended in 5 ml water and allowed to sediment for another five minutes. The supernatant was then discarded very carefully and the sediment was transferred to a slide which was then covered with a cover slip. The prepared slides were then examined under the microscope using the magnification level X_{40} for identification of trematode eggs and X_{10} for coccidian oocysts. The size of the eggs was measured using an eyepiece micrometer.

Recovered Helminths of nematode & larvae were identified after clearing in lactophenol ; large worms were morphologically identified after single staining with Aceto - Alum Carmine solution ; using valid references of Ohbayashi *et al.* (1972) , Pinto *et al.* (1994) and Noor-Un-Nisa (2001). Sections of muscles and brains were examined microscopically for any cysts after staining with H&E . Overall and the prevalence of zoonotic & nonzoonotic parasites in each host species were calculated as a percentage of infected individuals and the total number of individuals examined.

Preserved samples re-examination microscopically conducted at Al-Drora veterinary hospital during 2008.

Results

Seven species of Helminths and five species of protozoa were found in commensal rodents under study (Table1) .Cestode species recorded highest prevalence(55%) with $p < 0.000$ among nematodes and protozoa species respectively (Table 2) . *R. norvegicus* endoparasits recorded highest prevalence (55%) than other rodents (Table2 & Fig.1 &3) ; Meanwhile results showed zoonotic Helminths *H. diminuta* (12.5%) , *C. fasciolaris* (9%) in *R. norvegicus* ; *H. nana* (3.5%) and *Vampirolepis sp.*, (2.6 %) in *M. musculus* were highly prevalent , whereas zoonotic protozoa *T. lewisi* (5 %) , *Sarcocysts sp.* (4.1%) in *R. norvegicus* and *B. microti* (4.4%) in *R. rattus* showed highest prevalence under study. *T. gondii* and *Leishmania sp.* were not found in all rodents samples under study. Non zoonotic highly prevalent endoparasites results showed that *M. rodentium* (2.3%) and *T. musculi* (2.3%) in *R. norvegicus* ; *S. obvelata* (5.2 %) and *Trichuris sp.* (3.5%) in *M. musculus* respectively (Table 1) & (Fig. 2). New records for *Vampirolepis sp.* (synonym of *H. nana*) , *B. microti* and *Sarcocysts sp.* ; whereas negative results revealed for diagnosis of *T. gondii* and *Leishmania sp.* which is was first experiment tried known in Baghdad .

Table (1): Occurrence of endoparasits (heminths and protozoa) in rats and mice.

Parasite spp.	Rodent species			Total number
	<i>Rattus norvegicus</i>	<i>Rattus rattus</i>	<i>Mus musculus</i>	
N . 89 (47.9 %)	62 (33.3%)	35 (18.8%)	186	
<i>H. nana</i>	25 (7.3%)	0 0	12 (3.5%)	37 (10.7%)
<i>H. diminuta</i>	43 (12.5%)	15 (4.4%)	25 (7.3%)	83 (24%)
<i>C. fasciolaris</i>	31 (9%)	13 (3.8%)	0 0	44 (12.8%)
<i>M. rodentium</i>	8 (2.3%)	0 0	1 (0.3%)	9 (2.6%)
<i>Vampirolepis</i>	7 (2%)	2 (0.6%)	9 (2.6%)	18 (5.2%)
<i>sp.</i>				
<i>S. obvelata</i>	17 (5%)	6 (1.7%0)	18 (5.2%)	41 (11.9%)
<i>A. tetraptera</i>	8 (2.3%)	0 0	2 (0.6%)	10 (2.9%)
<i>Trichuris sp.</i>	5 (1.4%)	2 (0.6%)	12 (3.5%)	19 (5.5%)
<i>T. lewisi</i>	17 (5 %)	8 (2.3%)	4 (1.2%)	29 (8.4%)
<i>T. musculi</i>	8 (2.3%)	0 0	4 (1.4%)	12 (3.5%)
<i>B. microti</i>	8 (2.3%)	15 (4.4%)	6 (1.7%)	29 (8.4%)
<i>Sarcocysts sp.</i>	14 (4.1%)	0 0	0 0	14 (4.1%)
<i>T. gondii</i>	0 0	0 0	0 0	0 0
<i>Leishmania sp.</i>	0 0	0 0	0 0	0 0
	191 (55%)	61 (18%)	93 (27%)	345

Table (2) : Total occurrence of different parasite phyla in rodents collected .

Parasite class	<i>R. norvegicus</i>	<i>R. rattus</i>	<i>M. musculus</i>	n.	Pearson Chi ²
Cestode	114 (33%)	30(8.7%)	47 (13.6)	191(55%)	p<0.000
Nematode	30(8.7%)	8 9(2.3%)	32(9.3%)	70(20%)	
Protozoa	47(13.6)	23 (6.7%)	14(4.1%)	84(25%)	
total	191(55%)	61(18%)	93(27%)	345	

Aseel Sh. Abdulla, "Microalbuminuria, Cardiovascular Morbidity, and Mortality in Diabetic and Non-Diabetic Subjects in Kirkuk City"

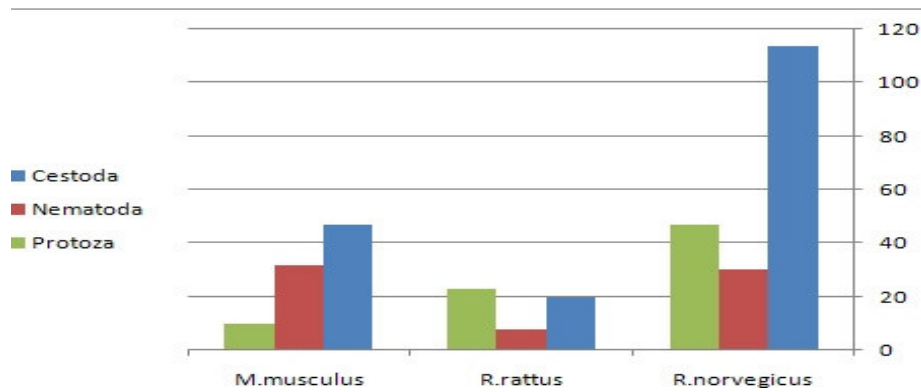


Figure (1): Total occurrence of different parasite classes in rodents species.

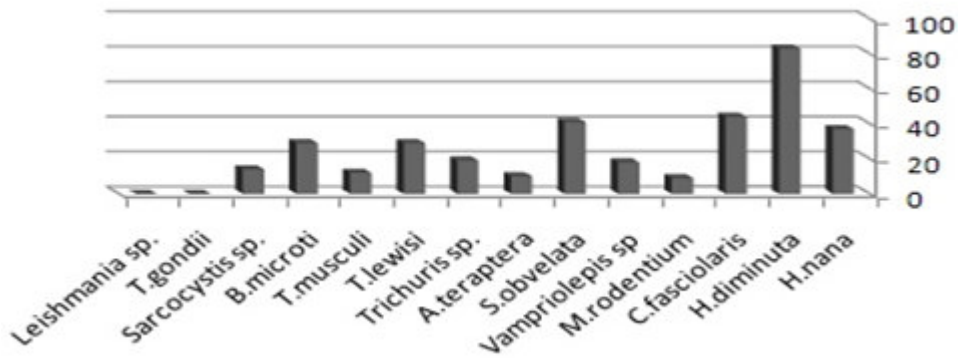


Figure (2): Zoonoti & nonzoonotic endoparasites of rodent species.

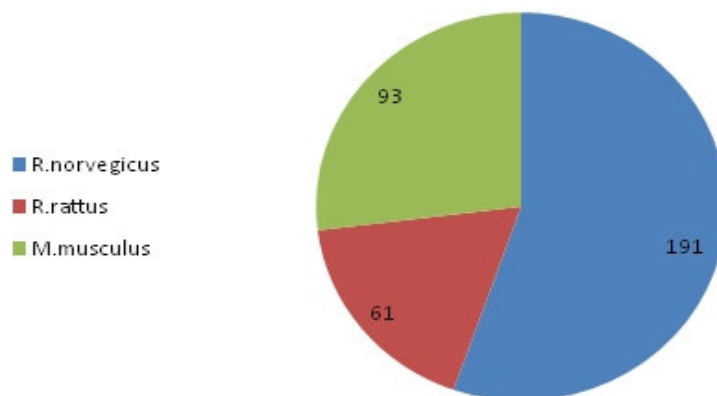


Figure (3) : Sum of endoparasites for rodent species.

Discussion

The diversity in rodent parasites under study, points to their adaptability as well as capability of the host to support them. In view of the diversity and zoonotic endoparasites, and the impoverished conditions prevailing in Baghdad districts where *in R. norvegicus*, *in R. rattus* and *M. musculus* highly prevalent survive, rodents can readily facilitate parasite transmission to humans and other susceptible animal hosts.

Heavy intestinal infection of rats & mice with zoonotic *H. diminuta* (24%) and *H. nana* (10.7%) agreed with studies of Mahmoud (1974) who reported *H. nana* 8.1% and *H. diminuta* 13.5%, while the present study disagreed with Al-Awsy (2005) who found low morbidity in rats (5.08%) and mice (4.48%), this difference could be related to the concentrated sampling from heavy rodent infested area parasitized with fleas ectoparasite and abundance of beetles that accomplished as intermediate host in their indirect lifecycles under study; beside that the high prevalence recorded could be elucidate and correlated with high prevalence of human Hymenolepiasis with *H.nana* 17.9 % and 7% in Baghdad & Alkhalis children (Al-Tae *et al.* 1998; Albaity 2000); in regarding to *C. fasciolaris* (Strobilocercus) Hydatigena type larval infection of *Taenia* sp. or probably of *Taenia taeniaformis* of cats which mostly collected from peritoneal or thoracic cavity of animals in this study agreed with Kamiya *et al.* (1987) who related this infection in *R.rattus* belongs to adult tape worm *Taenia* sp. mostly; this is a first recording mentioned this type in Iraq. The study recorded for first time, the prevalence of the zoonotic protozoa *B.microti* in Baghdad's rodents (4.4%) *in R. rattus*; *T. lewisi* prevalence results agreed with Molan and Hussein (1988) & differ in hosts only which could be due to the tick geographical distribution and host individual variation; 4.1% *Sarcocystis* sp. cysts were diagnosed from muscular tissue of *R. norvegicus* under study, which was lower than what O'donoghue (1987) who detected tissue cysts of *Sarcocystis* in the skeletal muscles of 16% 40 wild rodents of Indonesia, this could be attributed to scanty samples prepared from tissues in this study.

Negative results for diagnosis obtained for *T. gondii* and *Leishmania* sp. shared with the study of Kia *et al.* 2001 in Iran; nevertheless the trail considered as first experiment tried to detected these parasites due its huge public health importance [18].

Regarding non zoonotic endoparasites highly prevalent, *M. rodentium* (2.3%) and *T. musculi* (2.3%) in *R. norvegicus* while *S. obvelata* (5.2%) and *Trichuris* sp. (3.5%) in *M.*

musculus were recorded respectively, these results agreed generally with references mentioned previously; New records of *Vampirolepis sp.* (synonym of *H. nana*) under study brought an attention to this genus which is still arguable with genus *Hymenolepis* Weinland, 1858 and needs more investigations in Iraq.

The author is not aware of any other work on new records of *B. microti* and *C. fasciolaris* (Strobilocercus) Hydatigena type larval infection of *Taenia sp.* in rodents species in Baghdad area.

Acknowledgments

I would like to thank all Dr.s Kadhim Abd Alsaheb (recently FAO coordinator); Nawal Abd Alrazak; agriculture engineer Safia Kaky Pera Abd; & all officers in Baghdad department of endemic diseases in particularly Abd- Alhussain Alshamary. Great gratitude's offers to Dr. Samer Alwan director of Aldora veterinary hospital & Dr. Bushra Hazim for laboratory support and assistance.

References

- [1] Al-Barwari, E.; Nassir, J.K. and Zaia, M. (1987). Gastrointestinal helminthes of common rodents in Baghdad with the record of *Hymenolepis diminuta* from hamster. Iraqi J. Sci., 28(2): 299-308.
- [2] Al-Tae, A.A.; Risan, F.A. and Mirza, M.Y. 1998. Prevalence of intestinal parasites in children attending to Baghdad Medical City. J. Fac. Med. Baghdad, 40(4): 441-445.
- [3] Al-Awsy H.J.N. 2005. Prevalence of dwarf tapeworm in final host & its effect on some blood & biochemical parameters. M.Sc. thesis, College of Veterinary Medicine, University of Baghdad.
- [4] Aljeboori, T. and Evans, D.A. 1980. *Leishmania spp.* in Iraq. Electrophoretic isoenzyme patterns. I. Visceral leishmaniasis. Transactions of the Royal Society of Tropical Medicine and Hygiene, 74(2), 169-177.
- [5] Almorshidi, K.A. 2001. Parasitic infection in (*Rattus rattus*) & *Mus musculus* in Hilla city, M.Sc. thesis, College of Science, University of Babylon.
- [6] Anderson J. F., Mintz E. D., Gadbaw J. J., and Magnarelli L. A. 1991. *Babesia microti*, Human Babesiosis, and *Borrelia burgdorferi* in Connecticut. Journal of Clinical Microbiology, 29(12), 2779-2783.

- [7] Beaver , P. C.; Gadgil R. K. and Morera P. . 1979.Sarcocystis in Man: a Review and Report of Five Cases. Am. J. Trop. Med. Hyg. 28(5), 819-844.
- [8] Beaver, P. C., and R. C. Jung. 1985. Animal agents and vectors of human disease (5 th edition) Philadelphia: Lea& Febiger , 281.
- [9] Desjeux, P. 1991 .Information on the epidemiology and control of the leishmaniasis by country or territory. World Health Organization, Geneva.48.
- [10] Dubeya J. P., Bhaiyatb M. I., Macphersonc C. N. L., Allieb C. de, Chikwetob ,A., Kwoka O.C. H., and Sharmab R. N. 2006 Prevalence of *Toxoplasma gondii* in rats (*Rattusnorvegicus*) in Grenada, West Indies. Journal of Parasitology vol. 92(5):1107-1108.
- [11] Gratz ,N.G. & Ismail ,I.A.H .1986. Rodent – borne disease in countries of middle east . Proceedings of the second symposium on recent advances in rodent control , Kuwait 1986. E d. by Helmy Mohammad , A.H. , Zaghoul ,T. M. , Salit , A.M. & Zakria , M. State of Kuwait . Ministry of health . 1986 ,93-106.
- [12] Gratz N. G. 1974. The role of W.H.O. in the study and control of Rodent-borne disease. Proceedings of the 6th Vertebrate Pest Conference (1974). University of Nebraska - Lincoln Year 1974.
- [13] Hasson ,R.H. 2009.Density of commensal rodent species in Baghdad area. The Diyala journal of applied researches .(accepted for publication).
- [14] Ibrahim, E.A., M.A. Al-Zahrani, A.S. Al-Tuwaigri, F.J. Al-Shammary and D.A. Evans. 1992. *Leishmania* infecting man and wild animals in Saudi Arabia. 9. The black rat (*Rattus rattus*) a probable reservoir of visceral leishmaniasis in Gizan Province, southwest. Transactions of the Royal Society of Tropical Medicine and Hygiene, 86(5), 513-514.
- [15] Jawdat , S.Z. and Mahmoud , S.N.(1980).The incidence of cestoidean and acanthcephalan parasites of some rodents in Iraq. Bull. Nat. Hist. Res. Cent. , 7(4): 55-71.
- [16] Johnson, P. D. (1933). A case of infection by *Trypanosoma lewisi* in a child. Trans R Soc Trop Med Hyg 26, 467
- [17] Kamiya, M.; Ooi, H. K., Ohbayashi, M. and Ow-Yang, C. K. .1987. Bicephalic larval cestode of Taeniidae from rats in Malaysia. Jap. J.Vet. Res. 35(4): 275-282.
- [18] Kia ,E.B. Homayouni ,M.M. Farahnak , Mohebali ,A.M. & Shojai , S. ; 2001. Study of endoparasites of rodents and their Zoonotic Importance In Ahvaz, South West Iran . Iranian J. Publ. Health, 30(1-2), 49-52.

- [19] Kuticici V., Wikerhauser T., Gracner ,D. 2005. A survey of rats and mice for latent toxoplasmosis in Croatia: a case report .Vet. Med. – Czech, 50 (11): 513–514 .
- [20] Mahmoud , S.N. (1974) .Incidence and distribution of helminth parasites of the digestive tract of rats and mice of the family Muridae in Baghdad area, M.Sc. thesis , College of science, University of Baghdad.
- [21] Molan A.L, Hussein M.M. 1988) A general survey of blood and tissue parasites of some rodents in Arbil province, Iraq. Apmis Suppl. 3:47-9.
- [22] Molan, A.L., Hussein, M.M., Jasin, B.A. 1988. A general survey of intestinal helminths of some rodents in Arbil area. Iraqi J. Agri. Sci., ZANCO. 6(2): 69-79.
- [23] Nachai S., Montakan V., Bandit N., Nonglux A., Tiemjan K., Pranee R., Roger W. S. and Sathaporn J. 2007. Diagnosis of a Trypanosoma lewisi-like (Herpetosoma) infection in a sick infant from Thailand. Journal of Medical Microbiology 56, 1118–1121.
- [24] Noor-Un-Nisa. 2001. Studies on Helminths parasites of commensal and field rats in Karachi and some districts of Sindh . University of Karachi.
- [25] O'donoghue P.J., Watts C.H.S and Dixon B.R. 1987. Ultrastructure of Sarcocystis spp. (Protozoa Apicomplexa) in rodents from North Sulawesi and West Java, Indonesia .J. wildlife disease . 23 (2) , 225-232.
- [26] Ohbayashi , M., Toshiaki, M. . and Kubota, K .1972. Parasites of the Japanese shrew mole, *Urotrichus talpoides* temminck.. Jap. J. vet. Res. 20, 50-56 .
- [27] Pinto C.M, Ocaña-Mayorga S., Lascano M.S., Grijalva, M.J. 2006. Infection by trypanosomes in marsupials and rodents associated with human dwellings in Ecuador. J. Parasitology. Dec;92(6):1251-5.
- [28] Pinto R. M., Vicente J. J., Dely N., Gonçalves L., Gomes D. C..1994. Helminth Parasites of Conventionally Maintained Laboratory Mice. Mem. Inst. Oswaldo Cruz, , 89(1); 33-40.
- [29] Rifaat M.A, Mahdi A.H, Arafa M.S, Nasr N.T, Sadek M.S .1971. Isolation of Toxoplasma from Rattus norvegicus in Egypt. Trans. R. Soc. Trop. Med. Hyg. 65(6):788-9.
- [30] Senekji ,H. A.1940. Bacteriological and parasitological survey of rats in Iraq. Trans. R. Soc. Trop. Med. Hyg., 33 (6), 655-657.



Aseel Sh. Abdulla, "Microalbuminuria, Cardiovascular Morbidity, and Mortality in Diabetic and Non-Diabetic Subjects in Kirkuk City"

- [31] Shih ,Chien-Ming., Liu ,Li-Ping, Wen- Ching Chung, Ong , S. J., and Wang ,Chih-C Chien .1997. Human Babesiosis in Taiwan: Asymptomatic Infection with a*Babesia microti*-Like Organism in a Taiwanese Woman . Journal of Clinical Microbiology, 35(2), 450–454.
- [32] Shrivastava, K. K. & Shrivastava, G. P. (1974). Two cases of *Trypanosoma* species infection of man in India. Trans R Soc Trop Med Hyg. 68, 3–4.
- [33] Siński ,E.d, Bajer A., Welc R., Pawełczyk A., Ogrzewalska M. and Behnke J. M. .2006. *Babesia microti*: Prevalence in wild rodents and *Ixodes ricinus* ticks from the Mazury Lakes District of north-eastern Poland . International Journal of Medical Microbiology. 296(1), 22 May 2006, 137-143.
- [34] Stěrba J, Barus V. 1976 . First record of *Strobilocercus fasciolaris* (Taenidae - larvae) in man. Folia Parasitol (Praha). 23(3):221-6.

