

The Biochemical, Hematological and Histopathological Changes study induced by Tramadol and treated by Curcumin in Local Male Rabbits

Mohammed Abed Mahmood

Department of Pathology, Faculty of Veterinary Medicine, University of Diyala, Iraq
Correspondence E-mail: mohammedvet87@gmail.com

Abstract

The goal of current study to study the antioxidant effect of curcumin on biochemical, hematological parameters and histopathological effect on liver and kidney in male local rabbits. Twenty local male rabbits were used and divided randomly and equally into four groups, each groups with five rabbits. The first group injected with normal saline for two weeks. The second group given curcumin powder 50 mg/kg dissolved on corn oil by stomach tube daily for two weeks. Third group give tramadol tablets 200mg/kg one dose daily for two weeks and the four groups give curcumin followed by tramadol one dose for two weeks. The biochemical result showed no obvious difference between control group and second group, Group three showed increase in AST,ALT and ALP but these value return to normal in four group, total protein and albumin relatively normal in first ,second and four group while in third group showed decrease in value of it. The hematological parameters showed no difference of WBC in third group while the RBC and hemoglobin decrease in third group which treated with tramadol only, Platelets showed normal value in first, second group but decrease in third group . The histopathological study in liver showed normal histological section in first and second group, third group showed congestion of central portal vein, hepatocytic degeneration and congestion of sinusoids. In kidney the first, second group showed normal appearance of kidney structures but in the third group when used tramadol , the kidney showed enlarged hepatic vein, fibrosis and congestion of glumeruli. The used of curcumin before tramadol lead to decrease the histopathological lesion in both liver and kidney.

Keywords: Curcumin, tramadol, RBC, WBC, necrosis.



This is an open access article licensed under a [Creative Commons Attribution-NonCommercial 4.0 International License](https://creativecommons.org/licenses/by-nc/4.0/).

Introduction

The synthetic narcotic tramadol hydrochloride (TH) has effects that are comparable to those of codeine. It is an effective analgesic with broad applications, primarily in the management of moderate to extreme pain, including that caused by cancer, fibromyalgia, and musculoskeletal pain [1]. Withdrawal from opiates is specifically treated with tramadol hydrochloride, also used to alleviate migraine, osteoarthritis, and low back pain as well as early ejaculation [2]. TH changes how pain is perceived and how the body responds to it. (CNS). Additionally, it prevents norepinephrine and serotonin from being reabsorbed, which alters the ascending pain circuits [3]. various forms of tramadol including pill, capsule, drop, injection, suppository, and well-distributed as protein binding, it is pharmacokinetically active, rapid, and completely absorbed, The most severe side effects include confusion, hallucinations, convulsions, serotonin syndrome, and hypersensitivity response, which also result in the elimination of toxicant-damaged cells [4]. CNS and respiratory depression are two additional dosage toxicity signs. Lethargy can result in a cardiac arrest, coma [5]. Tramadol hydrochloride is metabolized in the liver and eliminated by the Curcumin has a number of notable qualities, including relatively low toxicity and adverse effects, excellent tolerance, and no research have been done on either animals or humans [6]. Unfortunately, there are still very few studies on curcumin and liver problems, and further research in this field is needed because liver diseases important reasons of death worldwide. curiosity among people all over the world. Numerous herbs turned into herbal complements that are said to support an active lifestyle. Curcumine is one of these herbs, which is derived from the roots of the turmeric plant and has a high potential for medical use

while being pharmacologically safe for both people and animals [7]. functions. When tramadol was injected into mature male albino rats, the parameters ALT, AST, and creatinine all increased [8]. The use of herbal natural goods has recently sparked Also curcumin consider anticoagulant, anti-inflammatory, antidiabetic and anticarcinogenic herbal treatment [9]. kidney; as a result of their involvement in drug metabolism, the liver and kidney are more susceptible to toxicity, which can impede their Traditional herbal remedies are increasingly being used to treat liver disorders on a global scale. Only a small number of the many physiologically active substances that have been found to be hepatoprotective in the scientific literature have effects potent enough to prevent various kinds of liver injury. Some of them, including silymarin and curcumin, have caught the interest of scientists [10]. The purpose of current study was to explore any curcumin protective effects on both liver and kidney tissues brought on by tramadol in rabbits. Investigations biochemistry , hematological and histopathology were all part of this study.

Materials and methods

Tramadol tablets 200 mg/ml manufactured by Cspc ouyi pharmaceutical co,LTd. china. In addition, curcumin powder from Sigma Company 50mg/kg dissolved in corn oil and given by stomach tube. Twenty male rabbits were used in current study. The rabbits weighing 1.5-2 kg and housed in clean ventilated cages, left for 3 weeks with health food and water before experimental study under 24 °C. Animal divided equally and randomly into four groups, each group with 5 animals and

received treatment (Table 1). The experimental duration continuous for 2 weeks, after that, animal sacrificed. All experimental study continue for two weeks.

Biochemical procedures

Clean and dry tube were used for collection of blood samples from control and other groups, centrifuged for ten min to obtain serum. Liver function were determined in this study including, alkaline phosphatase (ALP), aspartate transaminase (AST) and alanine transaminase (ALT). Detection of protein and albumin according to standard procedures.

Histopathological procedures

After ended of experiment, one centimeter obtained from liver and kidney and immediately fixed in 10 % natural buffer formalin, dehydrated in 50,70,85,90,100,100 of ascending concentration of ethanol, xylol for cleared in two steps, embedded in paraffin, section of sample by microtome (5 µm), Finally

stained with hematoxylin and eosin stain according to histopathological procedures [11].

Table 1: The experimental design.

Statistical analysis

Mean standard division expressed the data with SPSS (version 12.0). one-way analysis calculated the difference between group and the deference considered *P* value less than 0.05.

Experimental design	Group one (control group)	Group two (curcumin group)	Group three (Tramadol group)	Group four (curcumin + tramadol group)
Received	Normal saline	Curcumin powder at 50mg/kg every day liquefied in corn oil and give orally by stomach tube	Tramadol tablets 200mg/kg	Curcumin powder at 50mg/kg every day followed by tramadol tablets 200 mg/kg

Results

1.Biochemical results:

No obvious difference in the biochemical parameter between group one (control group) and group two (curcumin treated group only), (Table 2). Group three which treated with tramadol only showed increase in AST, ALT and ALP but these values return to normal in the group 4 because of received 50mg/kg of curcumin in addition to tramadol, compared with group 3 which received only 15 mg/kg of tramadol ($P < 0.001$), (Histogram 1 and 2). The one and two group showed return of total protein and albumin to normal level comparable with third group with treated with tramadol and show decrease in albumin and protein level. This result return

to normal value as in control group in the rabbits treated with curcumin with tramadol in-group four (Histogram 3).

2. Hematological results

Table 3 showed the hematological parameters. WBC not showed difference in group 3 (treated with tramadol) comparable with other group ($P>0.001$) while the RBC decrease in 3 group in the rabbits treated only with tramadol ($P<0.001$) which obvious in histogram one and two. Also rabbits in group 3 treated with tramadol showed decrease in Hb with the rabbits treated with curcumin with tramadol in group 4 respectively which showed normal RBC, WBC and Hb value and similar the control group which obvious in histogram 4 and histogram 5.

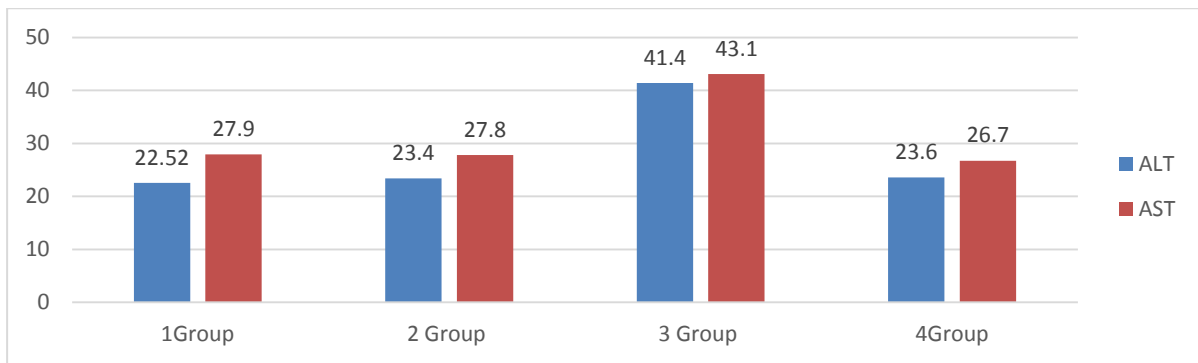
Platelets showed low value in rabbits treated with tramadol (group3) comparable with group one (control group) ($P>0.001$), but the platelets showed normal value in group 4 in rabbits treated with curcumin with tramadol and showed normal value of platelets as in control group ($P<0.001$), (histogram 6).

3. Pathological results:

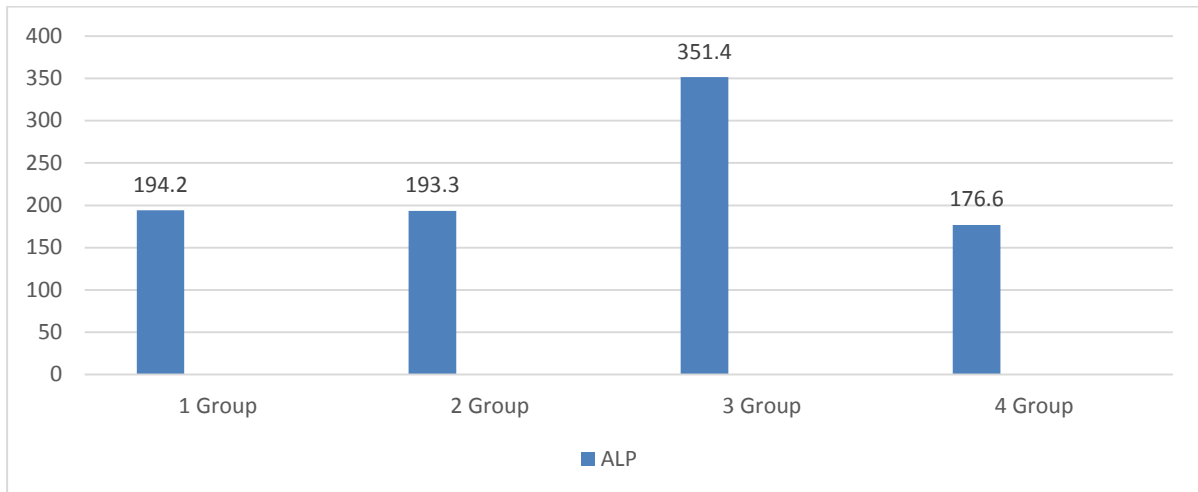
Control group of both liver and kidney showed normal histological structures (photomicrograph 1 and 5), also, in second group for two organ which treated with curcumin, the structure similar to normal and not occurred any obvious evidence (photomicrograph 2 and 6). Liver in third group when treated with tramadol only showed hepatocytic degeneration, congestion of sinusoid and central vein (photomicrograph 3), while the kidney showed congested glomerulus, congested renal vein and fibrosis (photomicrograph 7). Four group which characterized by given curcumin firstly and followed by tramadol lead to preservative the structures of liver and kidney and this may be to antioxidant effect of curcumin on this organ (photomicrograph 4 and 8).

Table 2: The results of biochemical tests in experimental groups of male rabbits.

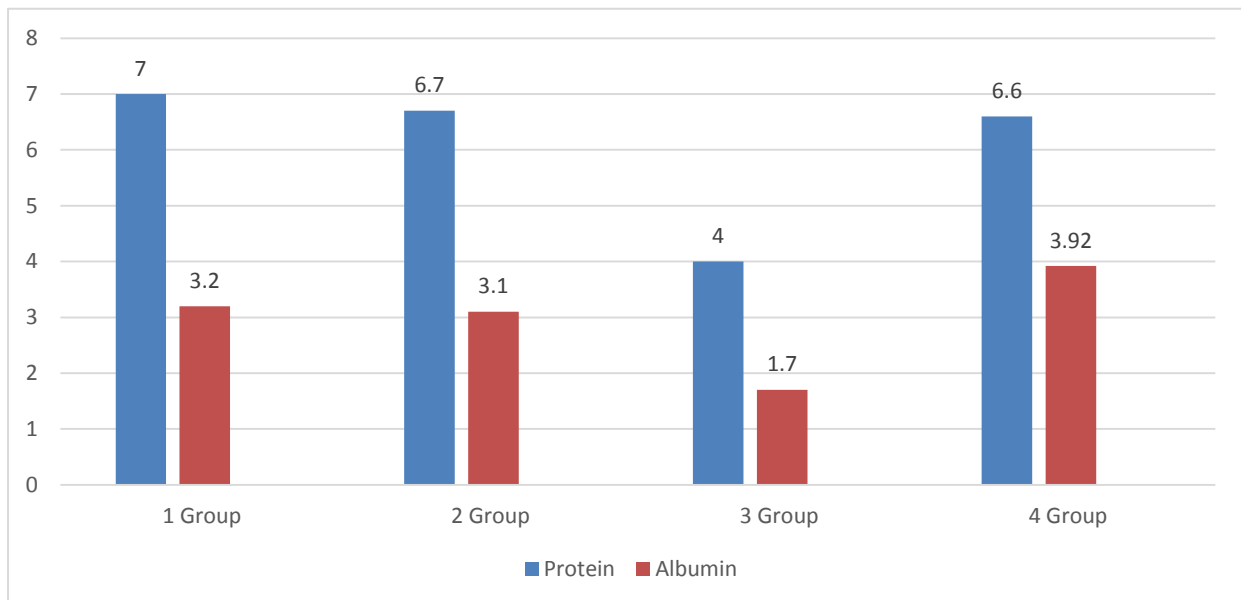
	ALT	AST	ALP	Total protein	Albumin
Group 1 Control	22.52 ± 2.2 ^a	27.9 ± 2.4 ^b	194.2 ± 22.0 ^c	7.0 ± 1.2 ^a	3.2 ± 0.5 ^b
Group 2 (curcumin)	23.4 ± 1.4 ^a	27.8 ± 2.9 ^b	193.7 ± 23.6 ^c	6.7 ± 0.6 ^a	3.1 ± 0.55 ^b
Group 3 (tramadol)	41.4 ± 3.5 ^b	43.1 ± 1.4 ^a	351.4 ± 27.4 ^a	4.0 ± 0.63 ^c	1.7 ± 0.16 ^a
Group 4 (curcumine and tramadol)	23.6 ± 2.8 ^a	26.7 ± 3.8 ^b	176.6 ± 36.4 ^c	6.6 ± 0.71 ^a	3.29 ± 0.72 ^b



Histogram 1: The results of ALT and AST in experimental groups of albino male rabbits.



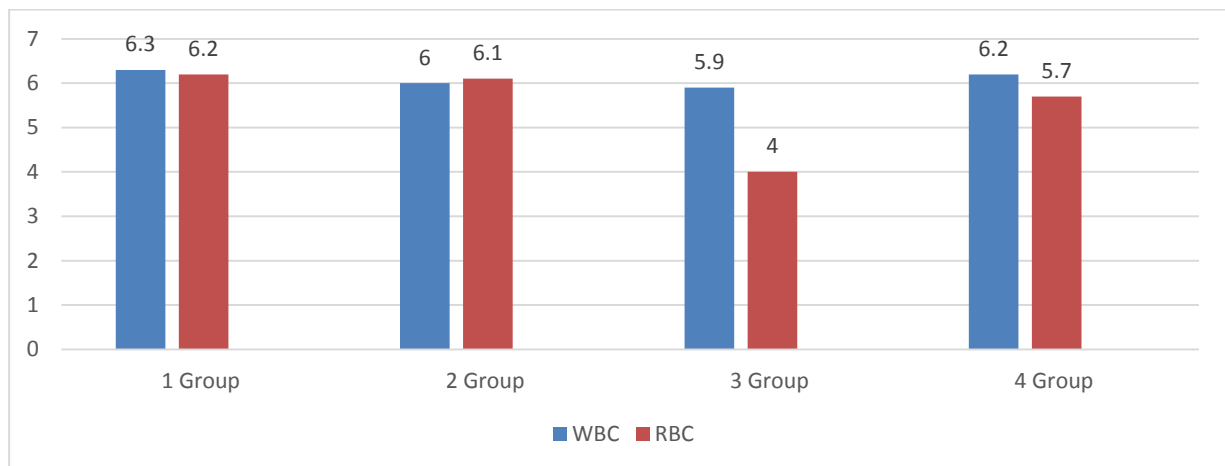
Histogram 2: The ALP in experimental groups of male rabbits.



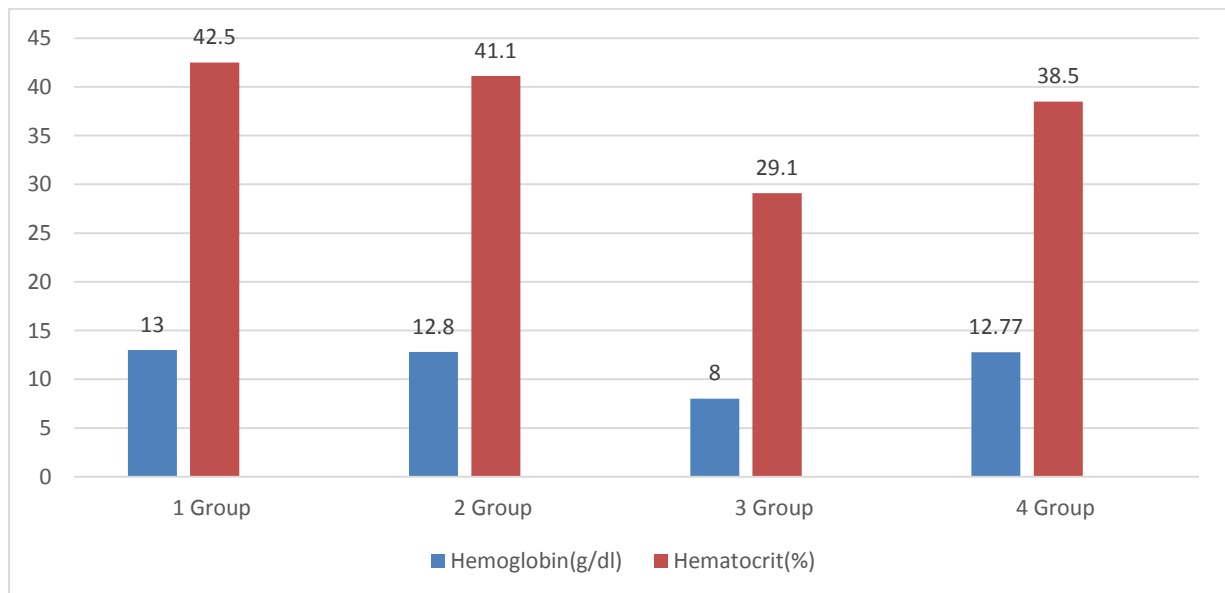
Histogram 3: The results of albumin and protein in experimental groups of male rabbits.

Table 3: The results of blood profile in experimental groups of male rabbits.

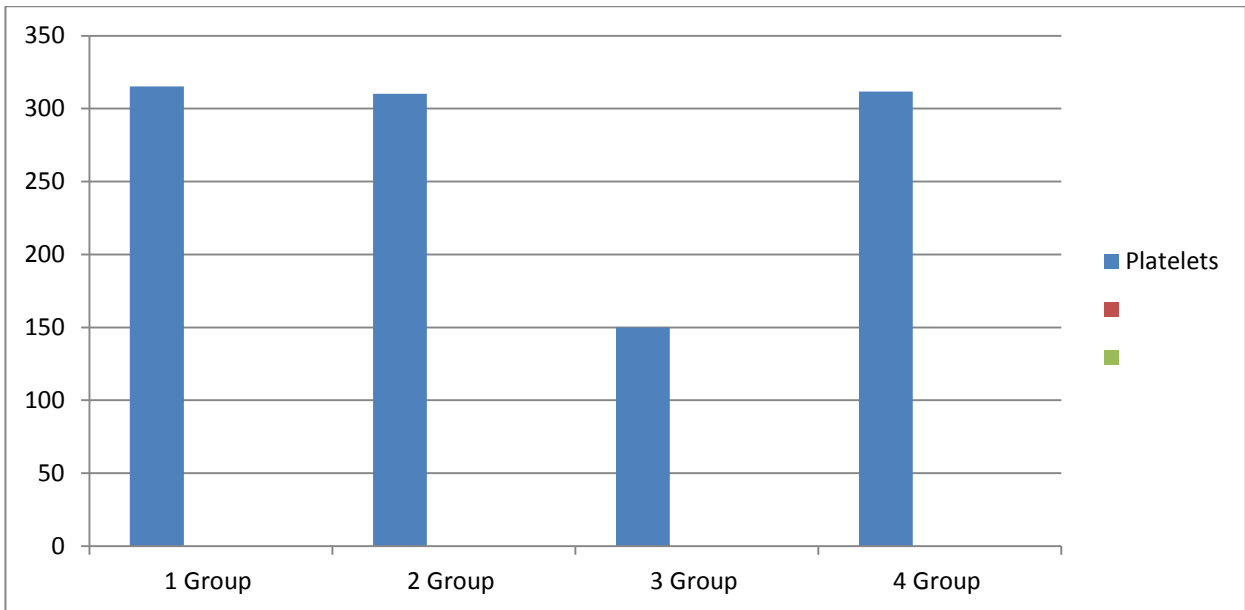
	WBC ($\times 10^3/\mu\text{l}$)	RBC ($\times 10^6/\mu\text{l}$)	HB (g/dl)	Hematocrits (%)	Platelet ($\times 10^3/\mu\text{l}$)
Group 1	6.3 ± 1.5^a	6.2 ± 0.6^b	13.0 ± 0.6^c	42.5 ± 0.5^a	315.2 ± 46.1^b
Group 2	6.0 ± 0.77^a	6.1 ± 0.56^b	12.8 ± 0.2^c	41.1 ± 0.7^a	310.1 ± 45.3^b
Group 3	5.9 ± 0.81^a	4 ± 0.18^a	8.0 ± 0.74^a	29.1 ± 0.7^b	149.9 ± 490.5^a
Group 4	6.2 ± 0.72^a	5.7 ± 0.14^b	12.77 ± 0.80^c	38.5 ± 0.48^a	311.8 ± 60.3^b



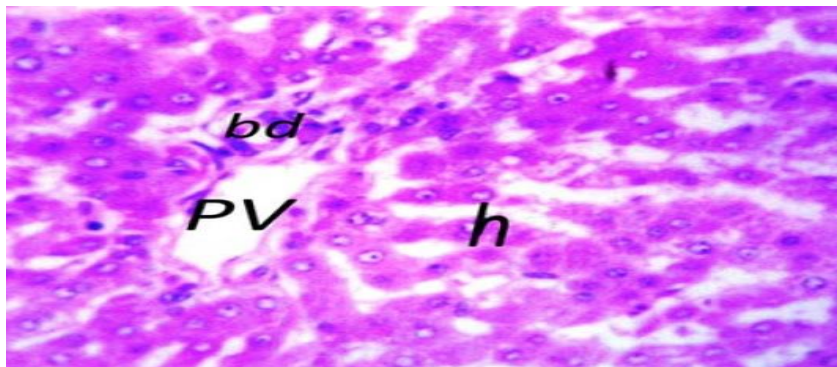
Histogram 4: The results of WBC and RBC in experimental groups of male rabbits.



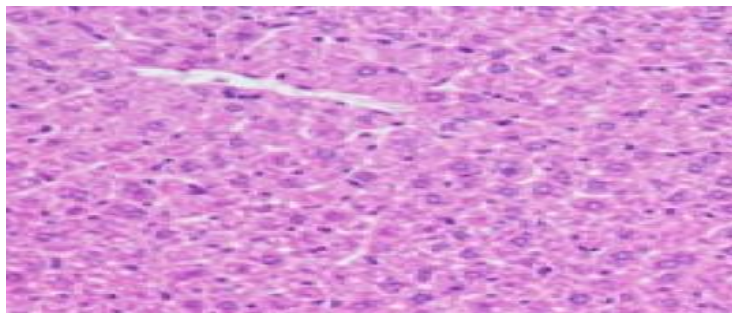
Histogram 5: The results of hemoglobin and hematocrit in experimental groups of male rabbits.



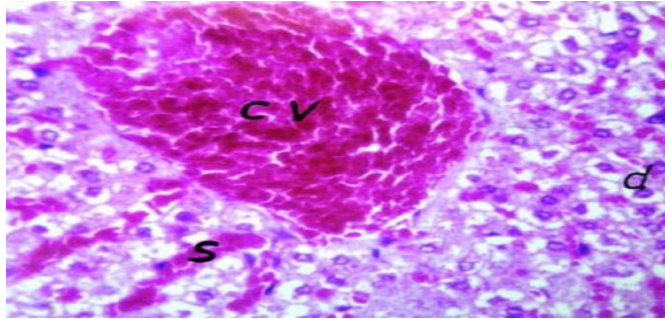
Histogram 6: The results of platelets in experimental groups of male rabbits.



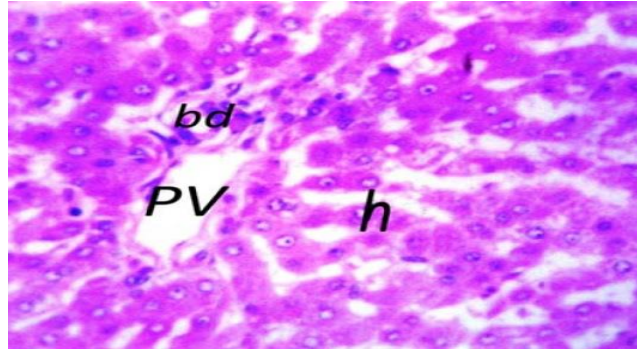
Photomicrograph 1: A histological section of liver in control group showed normal liver parenchyma (H & E stain; X40).



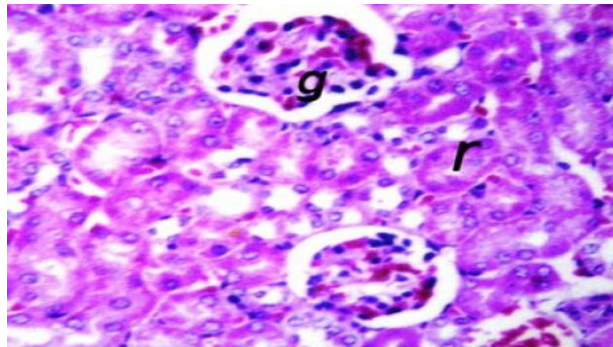
Photomicrograph 2: A histological section of liver in 2nd group showed normal liver parenchyma (H & E stain; X40).



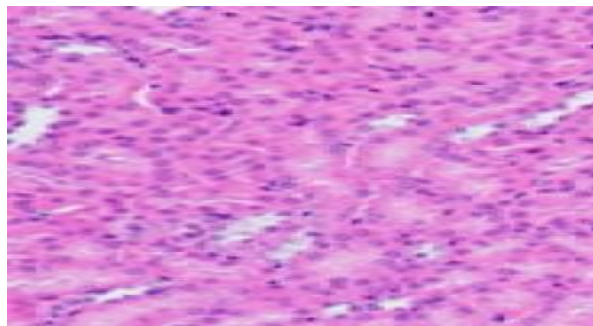
Photomicrograph 3: A histopathological appearance of liver in 3rd group showed hemorrhage in central vein , congestion in sinusoids and degeneration (H & E stain; X40).



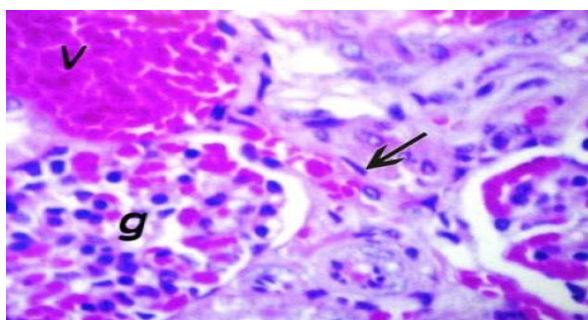
Photomicrograph 4: A histological appearance of liver in 4th group showed normal liver parenchyma (H & E stain; X40).



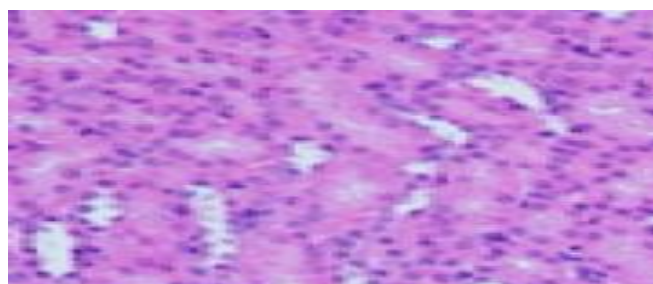
Photomicrograph 5: A histological appearance of kidney in control group showed normal glomerular and renal tubules (H & E stain; X40).



Photomicrograph 6: A histological appearance of kidney in second group showed normal kidney parenchyma (H & E stain; X40).



Photomicrograph 7: A histopathological appearance of kidney in 3rd group showed congested glomeruli (g), congested renal vein (v) and fibrosis (arrow) (H & E stain; X40).



Photomicrograph 8: A histological structures of kidney in 4th group showed normal parenchyma with presence of kupffer cells (H & E stain; X40).

Discussion

Liver consider important organ for drug metabolism, specially drug inducing liver injury which responsible about 50% of acute and chronic liver diseases [12]. One of the most common drug-related adverse effects in the world is tramadol, and one of the drug's main complications is liver damage. The liver function tests (AST,ALTandALP) indicate of hepatic function and the liver injury lead to increase of these markers [13]. The results showed increase in liver enzyme ALT,AST and ALP and decrease of plasma protein in addition to albumin in tramadol third group, elevation of ALT & AST indicated of necrosis in the liver [14]. This was in line with the findings of earlier researchers who looked at the impact of chronic tramadol use the protocol of 250 mg / 12 hours for two weeks on liver injury as determined by an increase in blood ALT levels. 9% of participants had ALT increase over seven times the highest limit

of normal, while 37% of participants had elevations four times of the highest limit of normal [15]. In this study, the histopathological finding inducing by tramadol was congestion of central portal vein in addition to hepatocytic degeneration, this aggremented with other study in 2015 [16]. [17]. This study shown that giving curcumin 1 hour befor taking tramadol lowered the rise in ALT,AST, in addition to ALP. The rise of enzymes in the bloodstream was entirely stopped by 50 mg/kg of curcumin. The value of ALT, AST, and ALP in these control, first, second groups did not differ statistically. These findings concurred with those of other researchers [18]. The major of enzymes is liver [19]. Tramadol-induced liver cell destruction may be the cause of the detected decrease in serum proteins and albumin. After concurrently administering curcumin and tramadol, these declining values were restored to normal levels. The microscopical structure of the liver and kidney of animals treated with

complication of curcumin and tramadol also supported the hepatoprotective effect of curcumin at dose (50mg/kg). as the liver recovered its normal structures. This study also showed that tramadol reduced the values of total red blood cells, hemoglobin and hematocrit, these findings were agreement with researchers who claimed that the injured liver cells are incapable of producing the hormone erythropoietin, which is necessary for the production of red blood cells [20]. Lower levels of circulating RBCs resulted in lower levels of hemoglobin and hematocrit. All of the aforementioned indicators showed a significant improvement with the adding of curcumin. Curcumin may utilize its anti-inflammatory effects via promoting of erythropoiesis and reducing damage to different blood cells [21]. Current study, tramadol-treated rabbits had lower platelet counts, which significantly increased with the addition of curcumin. This is consistent with a prior investigation that discovered tramadol induces platelet inhibition, raising the risk of surgical bleeding [22]. Following the administration of curcumin, an increase in platelet counts was seen. This was ascribed to curcumin's antioxidative effect in preserving blood platelets. [23]. The findings of the current investigation showed that curcumin significantly protected the liver from tramadol-induced liver damage. A decrease in ALP and plasma transaminases, as well as a rise in albumin and total plasma

References

- [1] S. A. Sheweita, Y. A. El-dafrawi, O. A. El-ghalid, A. A. Ghoneim, and A. Wahid, "Antioxidants (selenium and garlic) alleviated the adverse effects of tramadol on the reproductive system and oxidative stress markers in male rabbits," *Sci. Rep.*, vol. 12, no. 1, pp. 1–12, 2022, doi: 10.1038/s41598-022-16862-4.

protein, as well as an increase in red blood cells and platelet counts, were observed, served as strong evidence of this in the liver's histological inspection. Based on its antioxidant activity, curcumin has a protective effect against tramadol toxicity [8]. Other researchers [24]. have speculated that curcumin's anti-inflammatory and antioxidant defensive capabilities, as well as its capacity to scavenge free radicals, are what cause its positive benefits. They also claim that curcumin has ten times the antioxidant activity of vitamin E. Curcumin can also prevent nuclear factor-B from mediating the production of inflammatory cytokines [25].

Conclusion

The current study showed the tramadol lead to decrease of liver function parameters (ALT,AST and ALP), and decrease of hematological parameters in addition to histological changes on the liver while the curcumin lead to return these parameters value to the normal.

Conflict of Interests

The author declare that they have no conflicts of interest.

Funding statements

Current study was totally maintained by Pathological department, College of Veterinary Medicine University of Diyala.

- [2] M. Salem, A. Rizk, E. Mosbah, A. Zaghoul, G. Karrouf, and M. Abass, "Antinociceptive effect of lidocaine, tramadol, and their combination for lumbosacral epidural analgesia in rabbits undergoing experimental knee surgery," *BMC Vet. Res.*, vol. 18, no. 1, pp. 4–9, 2022, doi: 10.1186/s12917-022-03360-y.
- [3] A. Barakat, "Revisiting Tramadol: A Multi-Modal Agent for Pain Management," *CNS Drugs*, vol. 33, no. 5, pp. 481–501, 2019,

- doi: 10.1007/s40263-019-00623-5.
- [4] S. Grond and A. Sablotzki, "Clinical pharmacology of tramadol," *Clin. Pharmacokinet.*, vol. 43, no. 13, pp. 879–923, 2004, doi: 10.2165/00003088-200443130-00004.
- [5] K. Miotto, A. K. Cho, M. A. Khalil, K. Blanco, J. D. Sasaki, and R. Rawson, "Trends in Tramadol: Pharmacology, Metabolism, and Misuse," *Anesth. Analg.*, vol. 124, no. 1, pp. 44–51, 2017, doi: 10.1213/ANE.0000000000001683.
- [6] F. M. Kandemir, F. Benzer, N. C. Yildirim, and N. Ozdemir, "Compensatory effects of curcumin on cisplatin-induced toxicity in rabbit testis," *J Med Plants Res*, vol. 5, no. 3, pp. 456–461, 2011.
- [7] C. So-In and N. Sunthamala, "Treatment efficacy of Thunbergia laurifolia, Curcuma longa, Garcinia mangostana, and Andrographis paniculata extracts in Staphylococcus aureus-induced rabbit dermatitis model," *Vet. World*, vol. 15, no. 1, p. 188, 2022.
- [8] A. Elkhateeb, I. El Khishin, O. Megahed, and F. Mazen, "Effect of Nigella sativa Linn oil on tramadol-induced hepato- and nephrotoxicity in adult male albino rats," vol. 2, pp. 512–519, 2015.
- [9] X. Zhang *et al.*, "Antitumor effect of curcumin liposome after transcatheter arterial embolization in VX2 rabbits," *Cancer Biol. Ther.*, vol. 20, no. 5, pp. 642–652, 2019.
- [10] M. G. Rajesh and M. S. Latha, "Preliminary evaluation of the antihepatotoxic activity of Kamilar, a polyherbal formulation," *J. Ethnopharmacol.*, vol. 91, no. 1, pp. 99–104, 2004.
- [11] M. S. Dunnill, "Manual of Histopathological Staining Methods," *J. Clin. Pathol.*, vol. 26, no. 9, p. 728, 1973.
- [12] J. H. Hoofnagle and E. S. Björnsson, "Drug-induced liver injury—types and phenotypes," *N. Engl. J. Med.*, vol. 381, no. 3, pp. 264–273, 2019.
- [13] K. M. Najji, E. S. Al-Shaibani, F. A. Alhadi, S. A. Al-Soudi, and M. R. D'souza, "Hepatoprotective and antioxidant effects of single clove garlic against CCl₄-induced hepatic damage in rabbits," *BMC Complement. Altern. Med.*, vol. 17, no. 1, pp. 1–12, 2017.
- [14] D. H. Abdelhady *et al.*, "The ameliorative effect of Aspergillus awamori on aflatoxin B1-induced hepatic damage in rabbits," *World Mycotoxin J.*, vol. 10, no. 4, pp. 363–373, 2017.
- [15] R. I. Udegbunam, A. C. Onuba, C. Okorie-Kanu, S. O. Udegbunam, M. U. Anyanwu, and O. L. Ifeanyi, "Effects of two doses of tramadol on pain and some biochemical parameters in rabbits post-gastrotomy," *Comp. Clin. Path.*, vol. 24, pp. 783–790, 2015.
- [16] O. K. Ali, A. J. S. Ahmed, and A. G. Mawlood, "Effects of tramadol on histopathological and biochemical parameters in male rabbits," *Am. J. Biol. Life Sci.*, vol. 3, no. 3, pp. 85–90, 2015.
- [17] A.-B. M. Aref, "Tramadol Biological Effects, 2: Effective Therapeutic Efficacy of Lagenaria siceraria Preparation and Melatonin on Cell Biological, Histochemical and Histopathological Changes in Hepatocytes of Tramadol-Induced Male Mice," *Egypt. Acad. J. Biol. Sci. B. Zool.*, vol. 13, no. 2, pp. 105–119, 2021.
- [18] I. T. El- Ratel, T. E. H. Tag El- Din, and M. M. Bedier, "Beneficial effects of curcumin as a native or nanoparticles form on productive efficiency, liver and kidney functions, antioxidative status and immunity of heat- stressed growing rabbits," *J. Anim. Physiol. Anim. Nutr. (Berl.)*, vol. 104, no. 6, pp. 1778–1787, 2020.
- [19] S. A. Center, "Interpretation of liver enzymes," *Vet. Clin. North Am. Small Anim. Pract.*, vol. 37, no. 2, pp. 297–333, 2007.
- [20] A. M. Kazemifar, Z. Yazdi, A. Bedram, J. Mahmoudi, and M. Ziaee, "Effects of Intravenous Lipid Emulsion on Tramadol-Induced Seizure; a Randomized Clinical Trial," *Arch. Acad. Emerg. Med.*, vol. 9, no. 1, 2021.
- [21] S. M. Aboelhadid, S. El-Ashram, K. M. Hassan, W. M. Arafa, and A. B. Darwish, "Hepato-protective effect of curcumin and silymarin against Eimeria stiedae in experimentally infected rabbits," *Livest. Sci.*, vol. 221, pp. 33–38, 2019.
- [22] N. R. Elyazji, I. Abdel-Aziz, A. Aldalou, and O. Shahwan, "The effects of tramadol hydrochloride administration on the hematological and biochemical profiles of

- domestic male rabbits,” *IUG J. Nat. Stud.*, vol. 21, no. 2, 2015.
- [23] F. A. Khaled and R. A. Qataf, “Study the enhance role of Garlic and Curcumin on Hematolglcal parameters in male rabbits,,” *Int. J. Pharm. Life Sci.*, vol. 12, no. 8, 2021.
- [24] S. M. El-Bahr, “Biochemistry of free radicals and oxidative stress,” *Biochemistry*, vol. 1, no. 5567/5cjjnt, p. 11, 2013.
- [25] A. M. Gonzales and R. A. Orlando, “Curcumin and resveratrol inhibit nuclear factor-kappaB-mediated cytokine expression in adipocytes,” *Nutr. Metab. (Lond)*, vol. 5, pp. 1–13, 2008.