

## Histological Evaluation of Local Application of Flavonoid Extract of Capparis Spinosa on Wound Healing in Alloxan-Induced Diabetic Rats

Maryam Hameed Alwan (BSC)<sup>1</sup> and Ban A Ghani (BDS, MSc ,PhD)<sup>2</sup>

### Abstract

**Background:** In diabetes, there are big concerns regarding impaired wound healing and other tissue disorders. The time and quality of wound healing are affected by many factors. One of the medical sciences ' aims is short-term wound healing with decreased side effects Herbal products are more valuable in both prophylaxis and curative in slowed diabetic wound healing as compared to synthetic drugs A considerable number of researches have shown that capers plant has distinct biological effects, including antioxidant, anticancer and antibacterial activity. Phytochemical analysis reveals C. Spinosa has large amounts of bioactive compounds, including polyphenolic compounds, which are essential for its health-promoting effects.

**Objective:** Histological evaluation of the effect of topical application of flavonoid extract of Capparis spinosa on the healing of incisional cutaneous wounds in alloxan-induced diabetic rats.

**Patients and Methods:** A total of 30 healthy male Wistar rats weighing approximately 250-300 g were used in this study. A surgical incisional wound with full skin thickness of 1.5 cm length were done in cheek skin of each rat. All rats were randomly divided into following groups: Group A: (10 healthy rats) received daily local application of the plant extract. Group B: (10 alloxan-induced diabetic rats) received daily local application of extract of the plant material. Group C: (10 alloxan –induced diabetic rats) where normal saline was applied locally instead of plant extract. Assessment of wound contraction was done as well as epithelial thickness inflammatory cell count and blood vessels count. Scarification of all animals was done for the healing periods (3 and 7 days), and specimens were prepared for histological analysis.

**Results:** The results revealed that the recorded mean values of wound contraction increased with time in each group and that the highest mean values recorded in group A and B. Mean values of inflammatory cell count decreased with time lowest values recorded in group A after 7 days. Regarding epithelial thickness values increased with time. Blood vessels count showed highest mean value in group A at day 7.

**Conclusion:** Results from this study showed that flavonoid rich extract of Capparis spinosa enhances wound healing process in diabetic rats.

**Keywords:** Capparis spinosa, Wound Healing, Diabetic rats.

**Corresponding Author:** dr.ban61@yahoo.com

**Received:** 9<sup>th</sup> June 2019

**Accepted:** 16<sup>th</sup> June 2019

**DOI:**<https://doi.org/10.26505/DJM.18014700609>

<sup>1,2</sup> College of Dentistry - University of Baghdad- Baghdad -Iraq.

## Introduction

All wounds are matters in diabetes patient even the small one. A dramatic increase in chronic disease conditions was observed in the current quick lives, primarily diabetes, which is one of the main contributors to the real concern of wound healing. Diabetes is a metabolic disease identified by hyperglycemia that results in long-term destruction, dysfunction, and even the collapse of many tissues and organs, including eyes, kidneys, nerves, heart, and blood vessels. Impaired cutaneous wound healing is one of these complications of diabetes [1].

Diabetes is related to hyperglycemia and wound healing impairment through processes involving aggravation and inflammatory response chronification. Hard to cure wounds are a well-known complication of diabetes [2]. Despite the available treatment along with proper glucose control and meticulous wound care, the prognosis for wound healing is poor. The existence of multiple life-sustaining constituents in plants has encouraged researchers to concentrate on plants for their extensive healing wounds potential. Folklore traditions in Iraq use a big amount of plant extract to treat cuts, wounds, ulcers, swelling, and burns. Extracts of the plant are known as crude preparations are preferred due to unwanted side effects and efficacy [3]. Several studies have revealed that Capparis spinosa fruit provides many

biochemical compounds, such as flavonoids, which have a wide variety of activities [4]. Because of their broad pharmacological activities varying from antidiabetic and anti-inflammatory to anticancer effects, flavonoids are among the widest researched natural products with high free-radical scavenging activity, which helps to decrease the danger of chronic diseases[5].

## Patients and Methods

### Collection and identification of plant material

Fresh and ripe fruits of Capparis spinosa collected from different area of Iraq. The plant has been identified and authorized by the Department of Pharmacognosy and medicinal plants at AL-Mustansiriyah University \ College of Pharmacy. Fruits washed thoroughly in water, cut into small pieces and dried in shade at 25°C.

### Extraction of plant material

In the preparation of alcoholic extract, the dried fruit of Capers were grinded as powder and by using Soxhlet extractor 200 grams of capers plant powder was poured into one-liter flask and 70% ethyl alcohol was added as maintaining the level of powder covered. After 72 hours, the solution was filtrated and then the ethanolic extract was concentrated by evaporation under reduced pressure using rotary evaporator device at 50 ° C and rotation speed of 70 rpm to 1\3 original volume.

### Test for flavonoids

The presence of flavonoids has been determined using 5 ml of 5% NaOH was added to the extract followed by addition of 2ml 10% HCL. The formation of intense yellow color solution that turns colorless upon addition of HCL indicates the presence of flavonoids [6].

### Animal preparation

All of the procedures in the experiment were done in accordance with the animal experimentation ethical principles of Baghdad University/College of Dentistry. To calculate the alloxan dose given to them, all animals of (groups B and C) were weighted. The induction of diabetes achieved by intraperitoneal injection the rats with a single dose of (150 mg/kg B.W.) of the Alloxan[7].

Blood glucose was measured daily until the end of the experiment. After 12 h fasting, blood was obtained from the animal's tail. Animals with blood glucose levels higher than 200mg / dl were declared as hyperglycemia. After the general anesthesia was induced, surgical incision wounds with full skin thickness of 1.5 cm length were done in right cheek skin of each rat. Daily application of flavonoids rich extract of Capparis spinosa (doses of 200 mg/kg) was done for all the animals of group A and group B. All tissue samples were fixed in 10% neutral formalin and processed for conventional haematoxylin and eosin staining (H&E), for histological examination and to assess the inflammatory cells count with histomorphometrical analysis of epithelial thickness and blood vessels count.

### Statistical analysis

#### Estimation of wound contraction

The percentage of wound closure was determined by using the formula:  $((L1 - L2) / L1) \times 100$ , where L1 is the length of wound on the day 0, while L2 is the length of wound on the day of observation. Descriptive statistics of the percentage wound contraction revealed that the recorded percentage of mean values increased with time in each group and that the highest values were recorded in group A and group B in 3 and 7 days, these findings are shown in Table (1).

### Results

#### Histological

##### Three days duration

Group A: Histological view of wound site shows necrotic tissue at wound surface inflammatory cell infiltration, hair follicles, numerous congested blood vessels surrounded by granulation tissue with irregularly arranged collagen fibers and fibroblasts Figure (1) (2).

Group B: Histological view at wound site of diabetic rats after three days of Capparis Spinosa (CS) application shows epithelial cell migration with overlying remnant of necrotic tissue, new developing hair follicles. Other view shows remodeling collagen fibers with fibroblasts Figure (3)(4).

Group C: Microphotograph view of skin section shows necrotic tissue no epithelium is formed, infiltration of inflammatory cells. View of dermis shows remodeling granulation tissue, fibroblasts, blood vessels and inflammatory cells Figure (5)(6).


### Seven days duration

Group A: Histological view at wound site shows complete epithelialization, new hair follicles, blood vessels, remodeling granulation tissue Figure (7),(8).

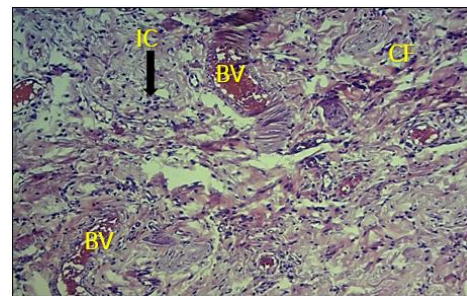
Group B: Histological view shows epithelium at surface which is underlined by accumulation of inflammatory cells. Magnified view shows dermis with numerous

blood vessels and inflammatory cells, collagen fibers and fibroblasts are seen too Figure (9),(10).

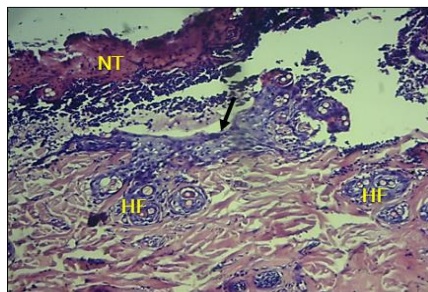
Group C: Microphotograph view shows wound surface sealed by epithelium invading the connective tissue surrounded by inflammatory cells, remodeling collagen fibers and hair follicles Figure (11),(12).



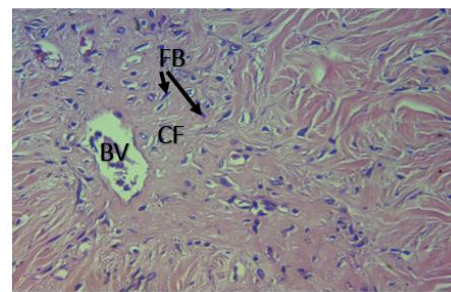
**Figure (1):** Photomicrograph of group A at day 3 shows necrotic tissue (NT) at wound surface inflammatory cells (IC) H&EX4



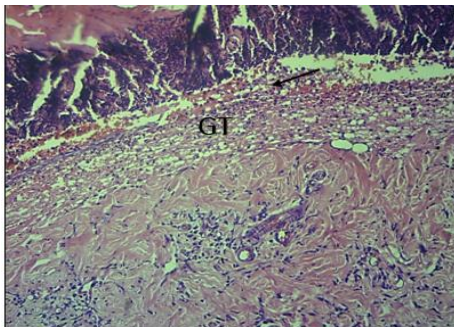
**Figure (2):** Photomicrograph of group A day 3 duration shows inflammatory cells (IC), congested blood vessels (BV), collagen fibers (CF) H&EX20



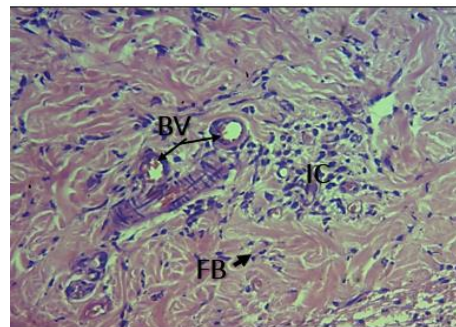
**Figure (3):** Photomicrograph of group B day 3 shows migration of epithelial cells at wound surface (arrow) newly formed hair follicles (HF) H&EX20



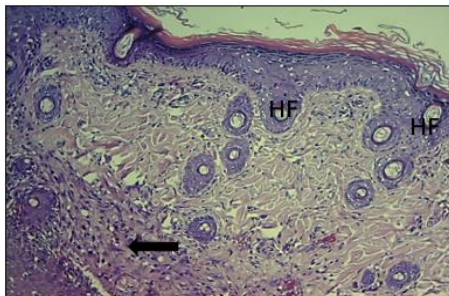
**Figure (4):** Photomicrograph of group B day 3 shows remodelling collagen fibers (CF), fibroblasts (FB), blood vessels (BV) H and E X20



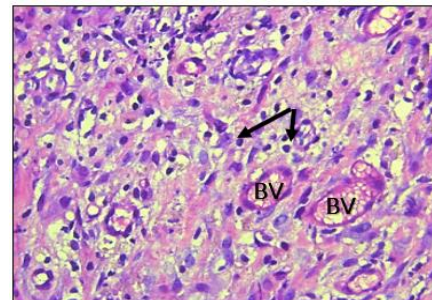
**Figure (5):** Photomicrograph of group C day 3 of shows inflammatory infiltration underlying necrotic tissue (arrow), granulation tissue (GT) H&E X10



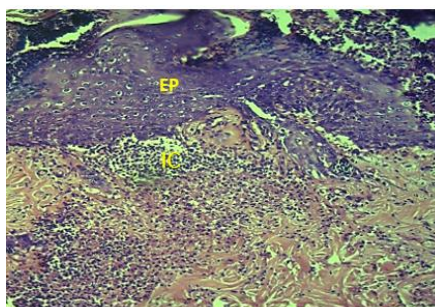
**Figure (6):** Photomicrograph of group C day 3 of shows remodeling collagen fibers (CF), fibroblasts (arrows), blood vessels (BV) with adjacent inflammatory cells (IC) H&Ex20



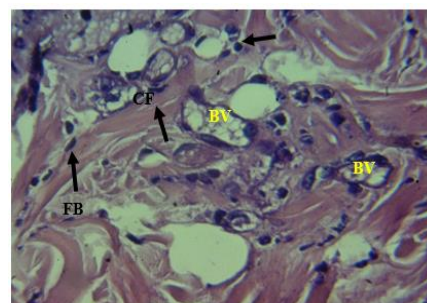
**Figure (7):** Photomicrograph of group A day 7 shows complete epithelialization, hair follicles (HF), remodeling fibers (arrows) H&EX20



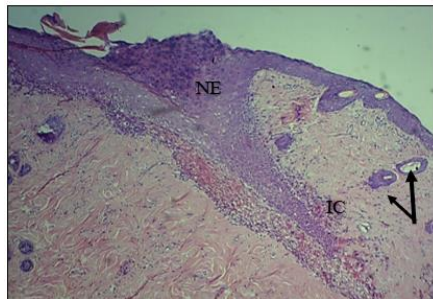
**Figure (8):** Magnified view at wound site group A day 7 show blood vessels (BV), inflammatory cells (arrow) H&E, X40



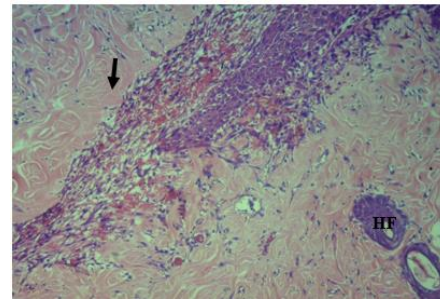
**Figure (9):** Photomicrograph of group B day 7 shows new epithelium, inflammatory cells (IC) H&EX20



**Figure (10):** Magnified view of wound site group B day 7 blood vessels (BV), inflammatory cells (IC), (arrows), collagen fibers (CF) and fibroblasts (FB) H&EX40



**Figure (11):** Photomicrograph of group C day 7 shows new epithelium (NE), inflammatory cells (IC), hair follicles (arrows) H&EX4



**Figure (12):** Higher magnification of previous Figure (11) shows remodeling collagen fibers (arrow) hair follicles (HF) H&EX10

### Inflammatory cell parameter

Counting the number of the inflammatory cells in five field Using light microscope with square grid in one eyepiece of the microscope; cells were counted under (power x40) lens, and then the mean number of cells was recorded for all healing periods [8]. The results showed that the mean values decreased with time in each studied group, the highest values were recorded in group C after 3 days and lowest values in group A in 7 days healing period, these findings are also demonstrated in Figure (13).

### Epithelial thickness parameter

Using power x40 lens, the epithelial thickness measurement was performed by the measurement of the distance from outermost layer of the keratin to the inner most basal layer of the epidermis at the wound edges as

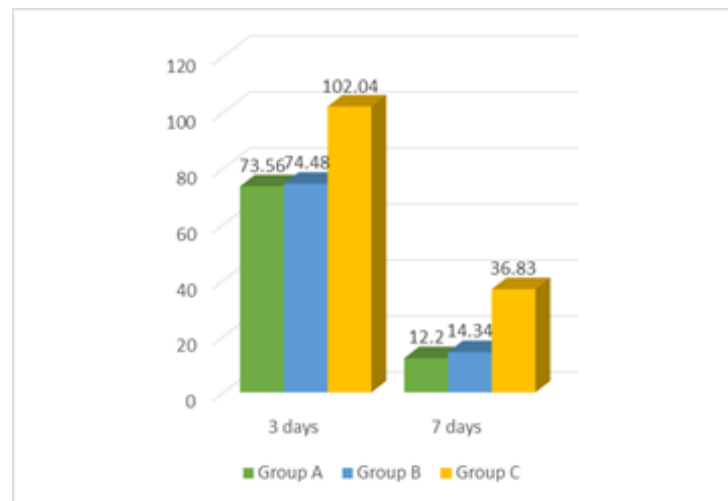
a mean of two readings by using Image J computer software. Highest mean values of epithelial thickness recorded in group A and group B in 7 days healing duration and the lowest mean value in group B in 3 days healing period, these findings are also demonstrated in Figure (14).

### Blood vessel count

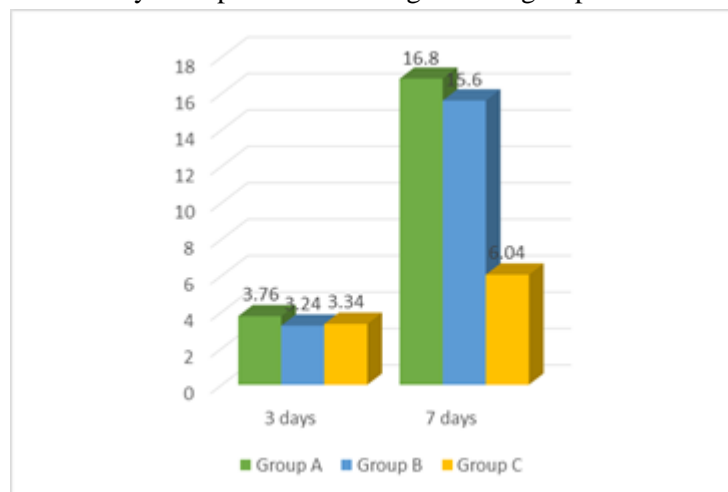
This process was done using Image J software. Using light microscope, under power x40, the numerical density of the blood vessels was determined in a  $45\mu\text{m}^2$  in 3 fields. Then the mean number of blood vessels was recorded [9]. The result revealed that the highest mean blood vessel values recorded in group A in 7 days healing period and the lowest mean value in group C in 3 days healing period, these findings are also demonstrated in Figure (15).

**Table (2):** Descriptive statistics of the percentage wound contraction (%) for all groups in each healing period

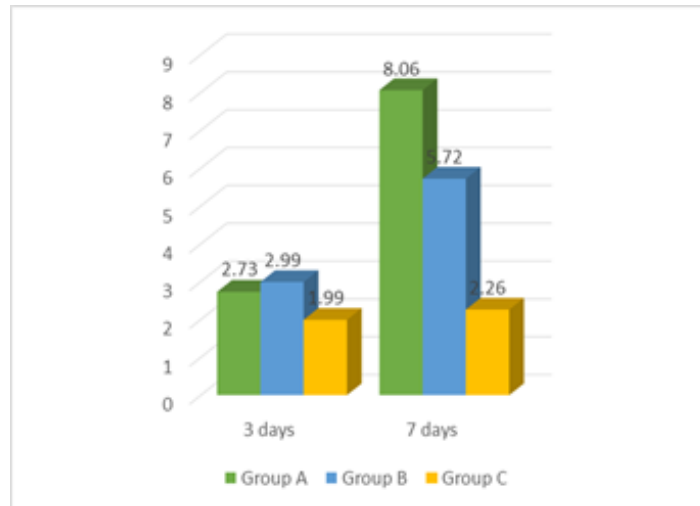
Days	Groups	N	Mean %	SD	SE	CI 95%		Min.	Max.
						Lower bound	Upper bound		
Day 3	Group A	5	25.24	5.45	2.43	18.63	23.05	20.00	33.00
	Group B	5	23.90	7.49	3.53	15.77	27.41	13.30	33.00
	Group C	5	18.64	5.56	2.49	6.44	22.09	13.30	26.60
Day 7	Group A	5	67.96	5.56	2.49	19.54	43.86	60.00	73.30
	Group B	5	61.30	9.90	4.42	33.57	48.92	46.60	73.33
	Group C	5	37.30	7.60	3.40	0.84	1.53	1.66	3.00



**Figure (13):** Inflammatory cells parameter among studied groups at different healing periods



**Figure (14):** Epithelial thickness in (µm) among studied groups at different healing periods



**Figure (15):** Blood vessel count among studied groups at different healing durations

## Discussion

Wound healing process relies on the tissue's reparative ability, the kinds and extent of damaged tissues and overall health conditions. Ideally, a safe therapy for wound healing should be considered as a therapeutic product that will enhance the development of new tissues without any adverse side effects [10]. Diabetes mellitus is one of the initial barriers and an important delaying agent to wound healing [11]. Wound healing in diabetes patients is compromised and delayed due to high blood glucose levels that obstruct cell proliferation and decrease the production of collagen, leading in reduced chemotaxis and phagocytosis [12].

Plant extracts are potential agents for wound healing and are mainly favored due to their extensive accessibility, non-toxicity, absence of unwanted side effects and their efficiency as crude preparations. A medicinal agent chosen for wound healing must enhance at least one stage of the healing

process without any side effects [13]. Capparis spinosa is a multi-purpose plant that contains a variety of chemically active compounds. We used it in our study because it was regarded as one of the herbals that used commonly in the traditional medicine and because of its composition of the flavonoids which was the major compound as so many studies have revealed anti-inflammatory, cell proliferative, immune modulating, collagen stimulating activity of *C. spinosa* [14], [15], [16]. Diabetic rats are regularly used in the evaluation of latest pharmacological products with a prospective role in the treatment of people with diabetes [17]. Accordingly, rats were selected as experimental model to carry on this study.

Wound contraction promotes the repair of tissue. The right equilibrium between too little contraction leading to non-healing injuries and too much contraction leading to contractures is essential for ideal healing.



[18]. The results of the present study, showed that percentage of wound contraction increased with time were highest in group (group A and group B) in agreement with the findings of (Kalantar et al.,2018) [16] where improvement in burn wound contraction in the rats treated by topical application of Capparis spinosa extract was detected.

### **Histological and histomorphometrical evaluation**

Wound healing is associated with a sequence of physiological response that include inflammation, cell proliferation and migration, angiogenesis, matrix formation, reepithelialization, and granulation tissue formation. The newly formed tissues compose of fibroblasts, collagen, oedema and fresh tiny blood vessels [10]. In this study the highest inflammatory cell count was noticed in group C at day 3 declined at day 7 which could be due to fact that diabetic wounds become halted in the inflammatory phase, which is characterized by a continuous flow of neutrophils releasing cytotoxic enzymes, free radicals and inflammatory mediators that trigger comprehensive collateral damage to the adjacent tissue. These damaging procedures counteract the healing process in such injuries, and the overproduction of free radicals that cause oxidative stress outcomes in detrimental cytotoxic impacts that interrupt wound healing [19] . Moreover faulted inflammatory phase causes defects in fibroblast migration, collagen synthesis and wound contraction [20], [21]. The inflammatory stage is a main step in diabetic wound healing which can promote reactive

oxygen species (ROS) [22] that have adverse effects on cellular proliferation [23]. In this study groups (A and B) recorded lowest values at day 7, this fact may be attributed to the anti-inflammatory effect of Capparis spinosa extract [24]. Findings obtained by (Majeed and Ghani ,2018) [25] who reported that rate of inflammatory cell infiltration decreased with time in experimental group treated by flavonoids extract of Hibiscus Sabdariffa as compared to control group which may indicate effect of flavonoid in promoting the healing process. The result disagrees with (Kim et al.,2011) [26] the number of inflammatory cells counts in the saponin-treated groups increased from day five to day seven. Flavonoids are strong anti-oxidants, which has anti-inflammatory properties and inhibits the release of histamine and other inflammatory mediators [27] this may promote and accelerate the healing process. Tajik et al.,2016 [8] showed that wound healing in rats was facilitated by topical application hydroalcoholic extraction of Capparis spinose in agreement with present findings.

The re-epithelialization and formation of granulation tissues is important, as it restores the integrity of the skin, making it less vulnerable to infection[28]. Chokpaisarn et al.,2017 [29] studied the effect of curcumin extract on wound healing and the microscopical examination showed partial re-epithelialization, loosely packed collagen fiber and in normal saline treated diabetic groups in contrast to experimental diabetic groups who received extract this was due to

the fact that accumulation of oxidative stress and inflammatory condition at the injury site is devastating to the healing process and concludes that the antioxidant and anti-inflammatory capacity of curcumin has improved wound healing in diabetic rats, in agreement with present results concerning histological examination of group B who received flavonoids extract of Capparis spinosa. The results of present study showed that after 3 days of skin incision epithelial thickness recorded lowest mean values in all groups then increased at day 7 in groups A and B which received flavonoids extract of Capparis spinosa, which disagree with results of Al-Kadhimi, 2015 [30] where highest recorded values of epithelial thickness were at days 3 and declined with time. Madkour et al., 2013 [11] reported that 7 days post wounding epithelial tissue regeneration, granulation tissue formation containing more proliferating blood capillaries (angiogenesis) with marked collagen deposition were also noticed. Transition from the inflammatory to the proliferative phase represents a key step during wound healing.

Flavonoids and their derivatives promote wound healing by reducing lipid peroxidation, thereby improving vascularity and preventing or slowing down the process of cell necrosis. Thus, increased level of flavonoids leads to increase in the viability and strength of collagen fibrils along with improved blood circulation [31], the result in the present study showed that neovascularization mean values were higher on days 3, 7 at the wound site of Capparis

spinosa treated groups (group A and group B), as compared to results recorded in group C, in agreement with the (Rodrigues et al., 2016) [32] findings which showed more new developed vessels in day three to fourteen day. The result disagrees with (Yuksel et al., 2014) [33] finding who stated that paroxetine made no difference in the number of blood vessels on the histopathologic sections of healing wounds in both healthy and diabetic rats. The angiogenesis processes are essential for wound healing and are impaired in diabetic patients, which subsequently slowed wound healing as reported by a study conducted by Kant et al., 2015 [34].

### Conclusions

The obtained results concluded that using Flavonoid rich extract of Capparis spinosa have potential activity in enhancing wound healing in diabetic rats.

### References

- [1] Baglama SS. oleuropein-rich olive leaf extract in diabetic rats A new dressing material in diabetic wounds : Wound healing activity of oleuropein-rich olive leaf extract in diabetic rats Diyabetik yaralar için yeni bir pansuman malzemesi : Diyabetik olan ve olmayan r. Gaziantep Med J. 2016;22(August):14–21.
- [2] Apelqvist J. The development of global consensus guidelines on the management of the diabetic foot. Diabetes Metab Res Rev. 2008;24(January):116–8.
- [3] Sachan AK, Vishnoi G, Kumar R. Need of standardization of herbal medicines in

- modern era. *Int J Phytomedicine*. 2016;8(3):300–7.
- [4]Hamuti A, Li J, Zhou F, Aipire A, Ma J, Yang J, et al. Capparis spinosa Fruit Ethanol Extracts Exert Different Effects on the Maturation of Dendritic Cells. *Molecules*. 2017;22(1):97.
- [5] Maggi F, Daglia M, Nabavi SF, Maggi F, Daglia M, Habtemariam S. Pharmacological effects of Capparis spinosa L. *Phyther Res*. 2016;1744(11):1733–44.
- [6]Hossain MA, AL-Raqmi KAS, AL-Mijizy ZH, Weli AM, Al-Riyami Q. Study of total phenol, flavonoids contents and phytochemical screening of various leaves crude extracts of locally grown *Thymus vulgaris*. *Asian Pac J Trop Biomed*. 2013;3(9):705–10.
- [7]Radenkovi M, Stojanovi M, Prostran M. Journal of Pharmacological and Toxicological Methods Experimental diabetes induced by alloxan and streptozotocin : The current state of the art. *J Pharmacol Toxicol Methods*. 2016;78:13–31.
- [8]Tajik M, Seifi S, Feizi F, Kazemi S, Moghadammia AA. Histopathological evaluation of hydroalcoholic extraction of capparisspinosa on the oral wound healing in rats. *J Babol Univ Med Sci*. 2016;18(12).
- [9]Carolina A, Wosgrau C, Jeremias S, Leonardi DF, Pereima MJ, Giunta G Di, et al. Comparative Experimental Study of Wound Healing in Mice : Pelnac versus Integra. *PLoS One*. 2015;10(3):4–13.
- [10]Tuhin RH, Begum M, Rahman S, Karim R, Begum T, Ahmed SU, et al. Wound healing effect of *Euphorbia hirta* linn. (*Euphorbiaceae*) in alloxan induced diabetic rats. *BMC Complement Altern Med*. 2017;17(1):423.
- [11]Fedekar Fadel Madkour, Mohsen Hassan, Waleed Khalil, Walied Abdo. Wound Healing Activity of Brown Algae plus Polyherbal Extract in Normal and Alloxan-induced Diabetic Rats . *J Adv Vet Res* . 2013;3(3):102–8.
- [12]Sanaei N, Mohammadi R, Raisi A, Zarei L. Extract of *Berula angustifolia* (L.) Mertens Enhances Wound Healing in Streptozotocininduced Diabetic Rats. *Wounds A Compend Clin Res Pract* [Internet]. 2018;30(8):242–52. Available from:<https://lopes.idm.oclc.org/login?url=http://search.ebscohost.com/login.aspx?direct=true&db=ccm&AN=131234651&site=ehost-live&scope=site>.
- [13]Amiri IA, Moslemi HR, Tehrani-Sharif M, Kafshdouzan K. Wound healing potential of *Capparis spinosa* against cutaneous wounds infected by *Escherichia coli* in a rat model. *Herba Pol*. 2015;61(2):63–72.
- [14]Arena A, Bisignano G, Pavone B, Tomaino A, Bonina FP, Saija A, et al. Antiviral and immunomodulatory effect of a lyophilized extract of *capparis spinosa* l. buds. *Phyther Res*. 2008;22(3):313–7.
- [15]Zhou H, Jian R, Kang J, Huang X, Li Y, Zhuang C, et al. Anti-inflammatory effects of caper (*Capparis spinosa* L.) fruit aqueous extract and the isolation of main phytochemicals. *J Agric Food Chem*. 2010 Dec;58(24):12717–21.
- [16]Kalantar M, Goudarzi M, Foruozaandeh H, Siahpoosh A, Khodayar MJ, Koshkghazi

- SM. The topical effect of Capparis spinosa L. extract on burnwound healing. *Jundishapur J Nat Pharm Prod.* 2018;13(1):7.
- [17]Lai AKW, Lo ACY. Animal Models of Diabetic Retinopathy: Summary and Comparison. *J Diabetes Res.* 2013;2013:1–29.
- [18]Ibrahim MM, Chen L, Bond JE, Medina MA, Ren L, Kokosis G, et al. Myofibroblasts contribute to but are not necessary for wound contraction. *Lab Invest.* 2015;95(12):1429–38.
- [19]Rosique RG, Rosique MJ, Farina Junior JA. Curbing Inflammation in Skin Wound Healing: A Review. *Int J Inflamm.* 2015;2015:1–9.
- [20]Khanna S, Biswas S, Shang Y, Collard E, Azad A, Kauh C, et al. Macrophage dysfunction impairs resolution of inflammation in the wounds of diabetic mice. *PLoS One.* 2010;5(3):e9539.
- [21]Koh TJ, DiPietro LA. Inflammation and wound healing: the role of the macrophage. *Expert Rev Mol Med [Internet].* 2011;13:e23. Available from: <http://www.ncbi.nlm.nih.gov/pubmed/21740602><http://www.pubmedcentral.nih.gov/articlerender.fcgi?artid=PMC3596046>.
- [22]André-Lévin D, Modarressi A, Pepper MS, Pittet-Cuénod B. Reactive oxygen species and NOX enzymes are emerging as key players in cutaneous wound repair. *Int J Mol Sci.* 2017;18(10):2149.
- [23]Perenack JD. Skin Incisions and Skin Closure. *J Oral Maxillofac Surg.* 2005;63(8):1–2.
- [24]El Azhary K, Tahiri Jouti N, El Khachibi M, Moutia M, Tabyaoui I, El Hou A, et al. Anti-inflammatory potential of Capparis spinosa L. in vivo in mice through inhibition of cell infiltration and cytokine gene expression. *BMC Complement Altern Med.* 2017;17(1):1.
- [25]Majeed SS, Ghani BA. Effect of Topical Application of Flavonoids Extract of Hibiscus Sabdariffa on Experimentally Induced Bone Defect. *J Baghdad Coll Dent.* 2018;30(1):33–8.
- [26]Kim YS, Cho IH, Jeong MJ, Jeong SJ, Nah SY, Cho YS, et al. Therapeutic effect of total ginseng saponin on skin wound healing. *J Ginseng Res.* 2011;35(3):360–7.
- [27]Tellechea A, Leal EC, Kafanas A, Auster ME, Kuchibhotla S, Ostrovsky Y, et al. Mast cells regulate wound healing in diabetes. *Diabetes.* 2016;65(7):2006–19.
- [28]Sahu R, Chaudhari A, Dennis V, Singh S, Pillai S, Dixit S, et al. Advances in Skin Regeneration Using Tissue Engineering. *Int J Mol Sci.* 2017;18(4):789.
- [29]Chokpaisarn J, Chusri S, Amnuakit T, Udomuksorn W, Voravuthikunchai SP. Potential wound healing activity of Quercus infectoria formulation in diabetic rats. *PeerJ.* 2017;5:e3608.
- [30]Al-Kadhimi BJ, Ghani BA. In Vivo Histological Evaluation of the Effect of the Topical Application of Estrogen Hormone on Wounds Healing in Ovariectomized Rabbits. *J Baghdad Coll Dent.* 2016;27(1):100–4.
- [31]Han G, Ceilley R. Chronic Wound Healing: A Review of Current Management and Treatments. *Adv Ther [Internet].*

2017;34(3):599–610. Available from:  
<http://www.ncbi.nlm.nih.gov/pubmed/28108895>  
<http://www.pubmedcentral.nih.gov/articlerender.fcgi?artid=PMC5350204>.

[32]amagata AS, Sato FT, Farsky SH, Curi R, Williner MR, Camara NOS, et al. Oral Administration of Linoleic Acid Induces New Vessel Formation and Improves Skin Wound Healing in Diabetic Rats. PLoS One. 2016;11(10):e0165115.

[33]Yuksel EP, Ilkaya F, Yildiz L, Aydin F, Senturk N, Denizli H, et al. Effects of paroxetine on cutaneous wound healing in healthy and diabetic rats. Adv Ski Wound Care. 2014;27(5):216–21.

[34]Kant V, Gopal A, Kumar D, Pathak NN, Ram M, Jangir BL, et al. Curcumin-induced angiogenesis hastens wound healing in diabetic rats. J Surg Res. 2015;193(2):978–88.