

**Physiochemical and histological studies on the effect of some
pollutants on fish and water of El-Garraf river**

PhD*Amany Mohammed Jasim,

**Physiochemical and histological studies on the effect of some pollutants on
fish and water of El-Garraf river**

PhD*Amany Mohammed Jasim,

* College of Medical& Health Technology, Baghdad

Received 10 June 2014 ; Accepted 26 October 2014

Abstract

This observation designed to measure some physiochemical parameters in samples of fresh water selected from El-Garraf river (one branch of Tigris river at Al –Kout city) to evaluate water quality and fish safety for human consumption. Samples were collected from three area of the river. pH, temperature, Biological Oxygen Demand (BOD) and the concentration of ammonia, nitrate, nitrite, Lead, Cadmium and mercury were also measured. Nineteen fish (*Cyprinus carpio*) were also collected from the similar areas of the river, specimens of gills, liver, kidney, gonads and intestine were taken for macropathological and histological studies. The results of physiochemical parameters of the present study were within the normal range of EPA standard of the rivers, the concentration of ammonia, nitrate and nitrite were above the permissible level based on WHO safety of the rivers, the obtained results of heavy metals indicated that water of river also polluted with Pb and Cd. Gross findings showed many abnormal alteration in gills and gonads of some fish studied. Several histological changes was also observed in gills represented by thickness of lamella, congestion and presence of area of hyperplasia with accumulation of mucus. Hepatic blood vessels of some fish showed dilation and haemorrhage as well as presence of necrosis and inflammatory cells within the blood vessels. Histopathological findings of intestine of some fish revealed degenerative and necrotic area of some lining mucosal epithelium and sloughing of the lining epithelium.

Keyword: Heavy metals, El- Garraf ,Tigris, pollutants, BOD, gross finding

Physiochemical and histological studies on the effect of some
pollutants on fish and water of El-Garraff river

PhD*Amany Mohammed Jasim,

دراسات فيزيوكيميائية ونسجية على تأثير بعض الملوثات على اسماك ومياه نهر الغراف

*د.اماني محمد جاسم

كلية التقنيات الصحية والطبية، بغداد

الخلاصة

صممت هذه الدراسة لقياس بعض العوامل الفيزيوكيميائية المؤثرة على المياه العذبة لنهر الغراف (احد فروع نهر دجلة في مدينة الكوت) لتقييم جودة مياه النهر وسلامة الأسماك للاستهلاك البشري جمعت عينات من ثلاث مساحات من النهروتم قياس كل من معدل الاس الهيدروجيني ,درجة الحرارة والطلب البيولوجي على الاوكسجين اضافة الى قياس تركيز كل من الامونيا والنترت والنترات وبعض المعادن الثقيلة مثل الرصاص والكاديوم والزنق.

اخذت ايضا عينات من الكبد والكلى و الغدد التناسلية والامعاء لعينات من الاسماك للدراسات الامراضية العينية والنسجية. اظهرت نتائج الدراسة ان معدلات المعلمات الفيزيوكيميائية لجميع العينات هي ضمن المعدلات الطبيعية القياسية لمياه الانهار لوكالة حماية البيئة , بينما كان تركيز كل من الأمونيا والنترات والنترت هو فوق المستوى المسموح به منظمة الصحة العالمية , كما أشارت النتائج بأن قسم من عينات مياه النهر كانت ملوثة ببعض المعادن الثقيلة (الرصاص والكاديوم) كما أظهرت الدراسات الامراضية العينية العديد من التغيرات غير الطبيعية في الخياشيم و الغدد التناسلية لبعض الأسماك ولوحظ ايضا وجود العديد من التغيرات في انسجة الخياشيم تمثلت بسمك الصفائح الخيشومية اضافة الى احتقان ووجود بعض المساحات التضخمية وتراكم افرازات مخاطية.

كما اظهرت مقاطع ماخوذة من اكباد الاسماك موضوعة الدراسة وجود اتساع غير طبيعي ونزيف اضافة الى مناطق تنخرية وخلايا التهابية داخل الاوعية الدموية لنسيج الكبد تم ملاحظة بعض الموجودات المرضية النسجية في امعاء بعض الاسماك تمثلت بوجود مناطق تنخرية في البطانة المخاطية الظهارية وانسلاخ واضح لبعض الخلايا البطانية الظهارية من طبقات جدار الامعاء.

الكلمات المفتاحية: المعادن الثقيلة، الغراف، دجلة، التلوث، الطلب البيولوجي على الاوكسجين , الموجودات العينية

**Physiochemical and histological studies on the effect of some
pollutants on fish and water of El-Garraf river**

PhD*Amany Mohammed Jasim,

Introduction

Natural aquatic systems may be in risk of highly contamination by pollutants such as petroleum, chemicals, solvents, oils and heavy metals[1].Large amounts of contaminations discharging by adjacent industries and hospitals into the aquatic systems leads to harmful effects on aquatic environment[2].Ammonia has a toxic effect on fish and healthy humans if the intake becomes higher than the capacity to detoxify[3].Nitrate also is one of the most important water contaminator, it can reach both surface water and groundwater as a consequence of agricultural activity or from waste water treatment and from oxidation of nitrogenous waste, the sources of nitrate are nitrogen cycle, industrial waste, nitrogenous fertilizer [2].Nitrite reactions in fresh water can cause oxygen depletion depending on the supply of oxygen in the stream of the rivers [4].

Biological oxygen demand (BOD) is the amount of oxygen needed by biological aerobic organisms in a body of water to break down the organic material present in water sample at certain temperature and over a specific time period. The term is also refers to a chemical procedure for determining this amount and commonly used as an indication of the organic quality of water [5].

Heavy metals like Lead, Copper, mercury, nickel, zinc, Cadmium, chromium and manganese are very toxic to the aquatic life. The commonest source of this heavy metal pollution is mining activities industrial exploration processing and effluent management, atmospheric condensation and sewage disposal [6].

Fish usually use to evaluate the health of aquatic ecosystems because pollutants build up in the food chain may a responsible for adverse effects and death in the aquatic life. Water borne metals may alter the biochemical and physiological parameters in fish tissues, these heavy metals cannot be destroyed through biological and may causes histological changes in gills and other tissue [7].

Physiochemical and histological studies on the effect of some
pollutants on fish and water of El-Garraf river

PhD*Amany Mohammed Jasim,

Material and Methods

Study areas and collection of samples: The study area was EL- Garraf river (one branch of the Tigris) at Al-Kout city, samples were collected from three areas during September and October 2014 as follows:

1-Water samples: Three samples were collected from each area of the river at depth 30 cm using glass bottles for physiochemical studies

Area A: from the edge of river next to the hospital of the city

Area B: from the middle of the river

Area C: from one of the edges of river

Other nine samples were also taken from the similar areas and depth (three samples from each area) approximately of 300 ml of each sample, put in bottles with a tight cover for biological oxygen demand (BOD) studies.

2-Fish samples: Nineteen fish (*Cyprinus carpio*) approximately 500-700 gram body weight which performed the important nutrient for human consumed in Iraq was collected from the similar river in plastic bags, transported to laboratory then examined externally and internally for gross lesions, changes in the internal organs were observed, photographed and specimens of gills ,liver ,intestine, kidney and gonads were taken for histopathological study

1- Physiochemical study: Temperature of water samples were immediately measured using thermometer ,pH also measured using pH -meter and the biological oxygen demand (BOD)was determined according the method of [8].The concentration of ammonia ,nitrate, nitrite were also measured according to[9] using spectrophotometer at the wave length set of 520 nm,507nm,520 nm respectively .The concentration of Pb,Cd and Hg also was determined by using flame atomic absorption spectrophotometric technique(FAAS) described by[10] water sample mixed with acetylene and nitrous oxide, the mixture was ignited in a flame whose temperature ranges from 2100 to 2800 °c during combustion, atoms of the elements in the sample was reduced to free, unexcited ground state atoms, which absorb light at wavelengths accurate 0.01-0.1nm. To provide element specific wavelengths, a light beam

Physiochemical and histological studies on the effect of some pollutants on fish and water of El-Garraf river

PhD*Amany Mohammed Jasim,

from a lamp whose cathode was made of the element being determined was passed through the flame, photomultiplier used for detect the amount of reduction of the light intensity due to absorption by the analyze, and this was directly related to the amount of the element in the water sample

2-Histological study: Fish specimens of gills, liver, intestine, kidney and gonads were taken. Samples were first weighted, fixed in formalin solution for forty eight hours, the selected tissues then dehydrated in ascending concentrations of ethanol series, embedded in paraffin and sectioned at 5 μm according to the method of [11]. Sections then stained with Hematoxylene and Eosin (H&E). All slides were examined under the light microscope

Statistical analyses were performed using SPSS version 17.0 for Windows (Statistical Package for Social Science, Inc., Chicago, IL, USA). Descriptive analysis was obtained the mean and standard deviation of the variables in concentration of the parameters included in this study.

Results

Results of physicochemical parameters illustrated in table (1) temperature values was less than 35°C , it was within the normal range of Environmental Protection Agency standards (EPA) of fresh water [12]. pH was slightly alkaline in area A (7.767 ± 0.0577) but, it was also with what recommended by EPA. The mean of BOD in all areas was complied with the standard of Environmental Protection Agency [12].

Results in table (2) revealed that the mean and standard deviation of the concentration of ammonia in areas A, B, C (0.41 ± 0.020 , 0.04 ± 0.001 , 0.16 ± 0.209 respectively) were above the permissible level based on WHO safety [13]. The mean and standard deviation of nitrite in area (A) was also above permissible level (0.13 ± 0.025) while it was with the normal range in area (B) and (C). The mean and standard deviation of nitrate in all areas studied were above what recommended by WHO standard (1.56 ± 0.060 , 1.09 ± 0.068 , 1.17 ± 0.044 respectively),

**Physiochemical and histological studies on the effect of some
pollutants on fish and water of El-Garraf river**

PhD*Amany Mohammed Jasim,

our result indicated that water of all area was polluted with ammonia and nitrate, while area A was polluted with nitrite

Table(3) shows the mean and standard deviation of the concentration of heavy Pb,Cd, Hg in water samples studied, the mean concentration of Pb and Cd was above what recommended by WHO in area A (0.05100 ± 0.001000 , 1.09 ± 0.068) while the mean concentration of Hg was with the permissible levels of the WHO safety standard in all water samples, our result indicated that water of area A was polluted with Pb and Cd heavy metals.

Macropathological finding:Gross findings showed many abnormal alteration in gills which represented by increase of mucus secretion, fusion and shortening of some filaments of gills (figure 3).The most common abnormalities in the morphology of visceral organs of some fish was the presence of congestion and external hemorrhage in gonads(figure 4) with pale liver appearance.

Histological examinations: Several histological changes was observed in gills of some fish studied represented by thickness of lamella, congestion and sinus of the primary lamellar layer (figure 5), epithelial tissue showed area of hyperplasia with accumulation of mucus cells at the edge of the secondary lamella (clubbing of secondary lamella) and haemorrhage (figure 6) .

Hepatic blood vessels of some fish showed dilation and haemorrhages with intravascular haemolysis of some red blood cells and activation of Kupffer cells (figure7) as well as presence necrosis and inflammatory cells within the blood vessels (figure 8). Histopathological findings of intestine of some fish recorded degenerative and necrotic area of some lining mucosal epithelium, sloughing of the epithelium lining of tip of some villi (figure9).No histological changes were noticed in kidney in all fish studied examined.

Physiochemical and histological studies on the effect of some
pollutants on fish and water of El-Garraf river

PhD*Amany Mohammed Jasim,

Table (1) The mean and standard deviation of temperature pH and BOD in water
samples of selected areas

Parameter	Values N=3 , Mean±SD			*EPA Standarad
	Area A	Area B	Area C	
Temperature (°c)	34.33 ± 0.577	32.67 ± 0.577	33.67± 1.528	Less than 35 °c
PH	7.767 ± 0.0577	7.02 ± 0.076	7.36 ± 0.079	6.5-8.5
BOD mg/L	0.13 ± 0.025	0.13 ± 0.025	0.12 ± 0.024	Less than 5

*Environmental Protection Agency

Table (2) The mean and standard deviation of ammonia , nitrite and nitrate in water
samples selected from areas studied .

Parameter	Values N=3 , Mean±SD			*WHO Unite
	Area A	Area B	Area C	
Ammonia (NH ₃ mg/L)	0.41 ± 0.020	0.04 ± 0.001	0.1 ± 0.209	0.03mg/L
(Nitrite mg/L) NO ₂	0.13 ± 0.025	0.09 ± 0.005	0.09 ± 0.002	0.1 mg/L
(Nitrate mg/L) NO ₃	1.56 ± 0.060	1.09 ± 0.068	1.17 ± 0.044	1 mg/L

*World Health Organization

Physiochemical and histological studies on the effect of some pollutants on fish and water of El-Garraf river

PhD*Amany Mohammed Jasim,

Table (3) The mean and the standard deviation of heavy metals (Pb, Cd , and Hg) in water sample from thee area of the river studied (N=3 , Mean±SD)

Water Sample	Pb(mg/L)	Cd(mg/L)	Hg (mg/L)
Area A	0.05100 ±0 .001000	0.01267 ± 0.002082	0.000800 ± 0.0001000
Area B	0.03200 ± 0.003464	0.00767 ± 0.000577	0.000133 ± 0.0000577
Area C	0.03300 ± 0.002646	0.00867 ± 0.000577	0.000233 ± 0.0001155
WHO unite	0.05	0.01	o.001

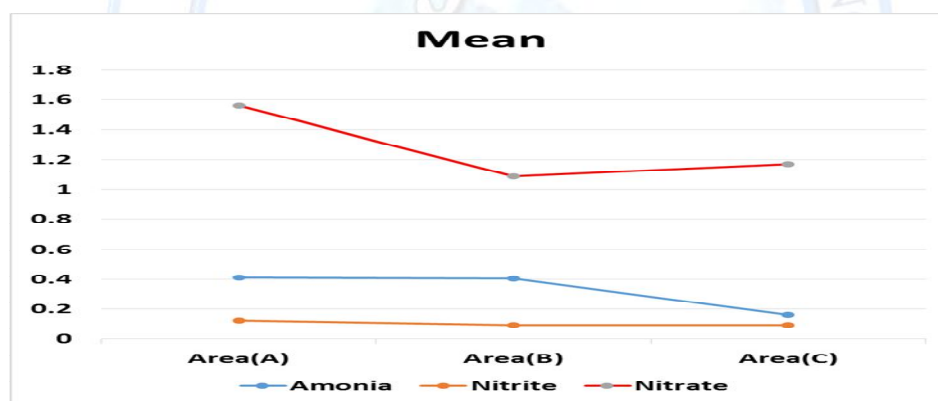


Figure (1) the mean concentration of ammonia, nitrite and nitrate and in water sample studied

Physiochemical and histological studies on the effect of some pollutants on fish and water of El-Garraf river

PhD*Amany Mohammed Jasim,

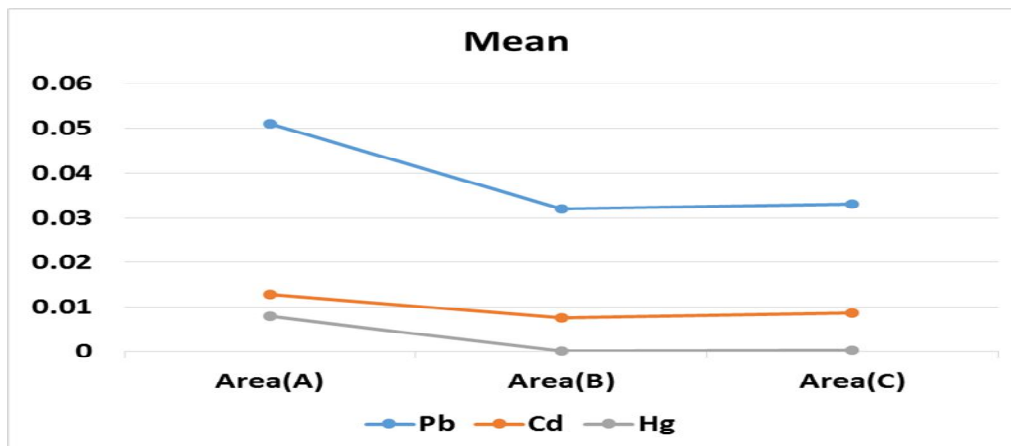


Figure (2) The mean concentration of the heavy metals(Pb,Cd,Hg) in water samples studied

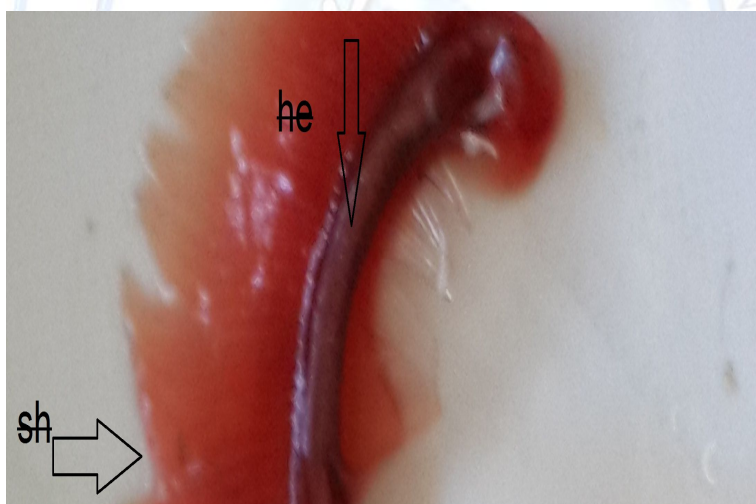


Figure (3) Photograph of gills showed hemorrhage and shorting in some filaments

he: hemorrhage

sh: shorting of filaments

Physiochemical and histological studies on the effect of some pollutants on fish and water of El-Garraf river

PhD*Amany Mohammed Jasim,

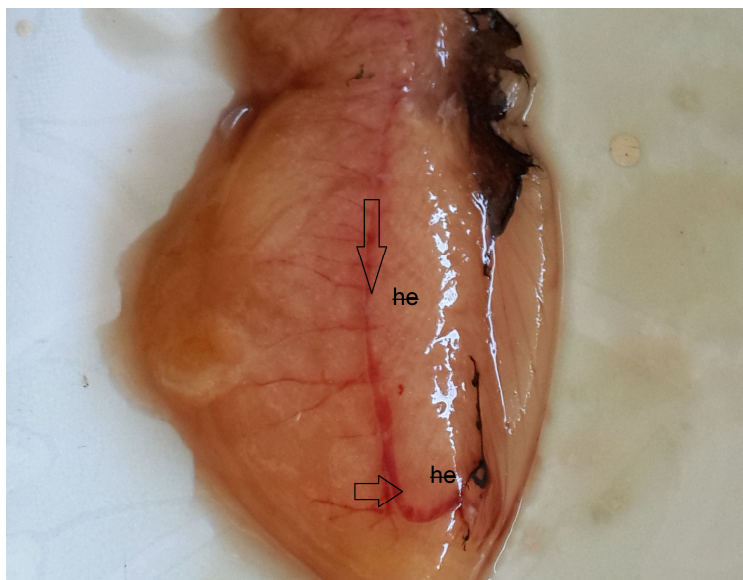


Figure (4): Photograph of gonads raveling congestion and external hemorrhage

he: external hemorrhage

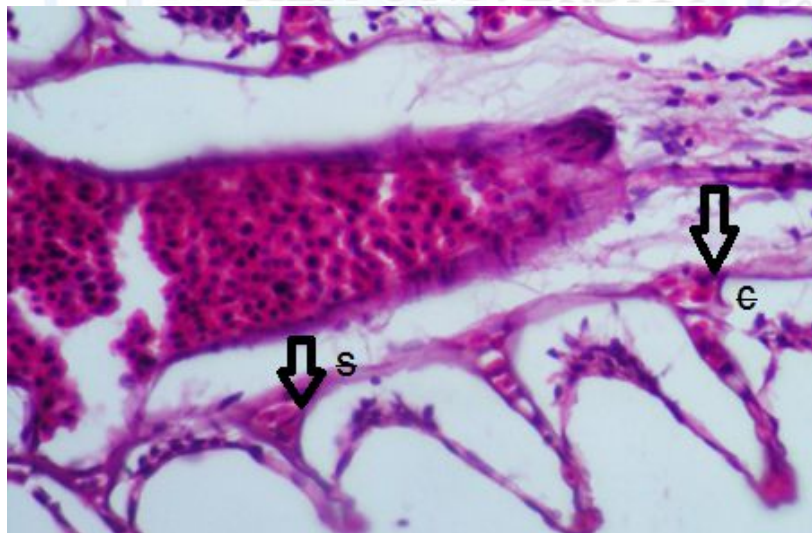


Figure (5): Photomicrograph of gills section showing congestion and sinus of the primary lamellae. C: congestion s: sinus (H&E X400)

Physiochemical and histological studies on the effect of some pollutants on fish and water of El-Garraf river

PhD*Amany Mohammed Jasim,

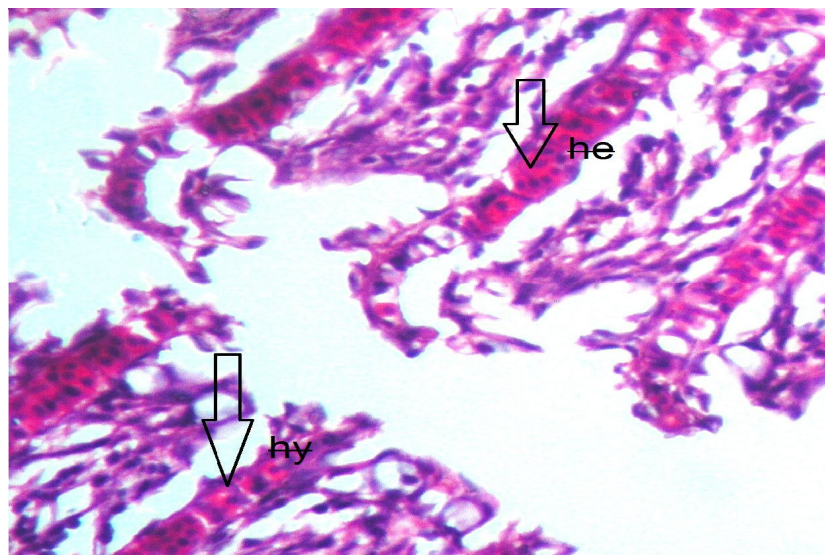


Figure (6): Photomicrograph of section in gills showing hyperplasia and internal hemorrhage (H&E X 400). hy: hyperplasia he :hemorrhage

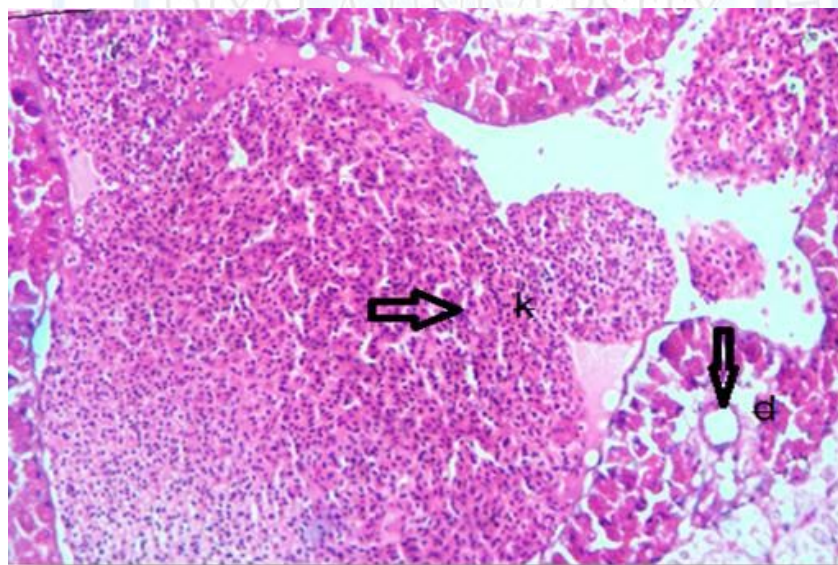
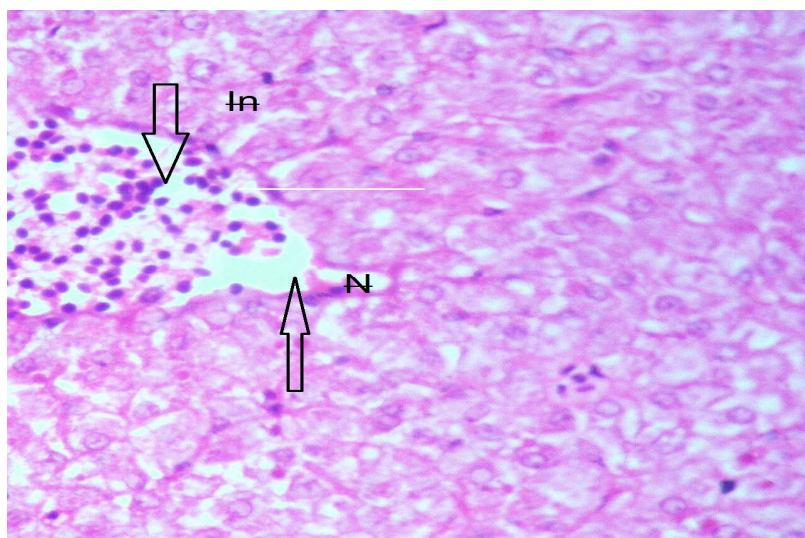


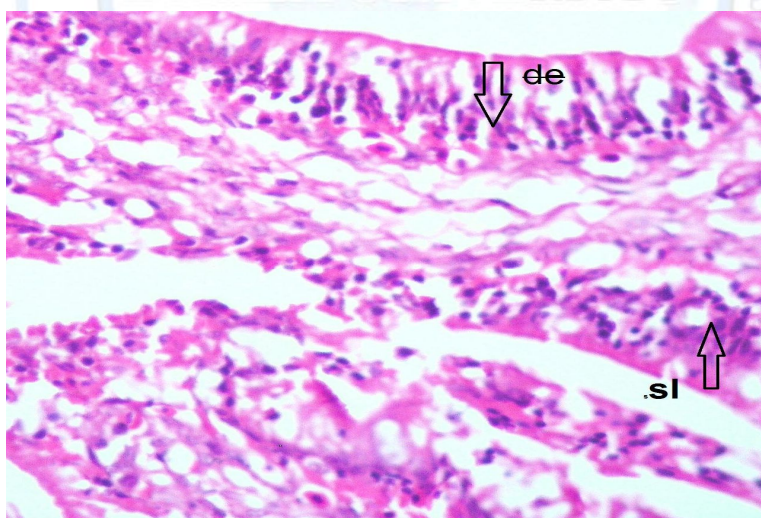
Figure (7): Photomicrograph of section liver showing dilatation of vessel and activation in a large amount of Kupffer cells (H&E X 400). d : dilatation of vessel k : Kupffer cells

Physiochemical and histological studies on the effect of some pollutants on fish and water of El-Garraf river

PhD*Amany Mohammed Jasim,



Figure(8): Photomograph of section in liver section showing necrotic area in the hepatic cells with presence of inflammatory cells (H&E X 400). N: necrotic area In: inflammatory cells



Figure(9): Photomograph of section of intestine showing degenerative changes with sloughing of some lining epithelium(H&E. X 400)

d:degeneration lining mucosal epithelium sl:sloughing of epithelium.

**Physiochemical and histological studies on the effect of some
pollutants on fish and water of El-Garraf river**

PhD*Amany Mohammed Jasim,

Discussion

Fresh water considered as human uses for maintenance of life, it is usually exposed to environmental pollution including chemical, physical and biological aspects that might alter the natural of this water to be risky for human users and aquatic life, water temperature considered one of vital factor for water habitat as it affects the dissolving of salts and gases especially oxygen and carbon dioxide, pH of the aquatic system is an important indicator of the water quality and the pollution in watershed areas [14]. The present study showed that pH and temperature of water of the river was compiled to the EPA standard. Also documented that river polluted with ammonia, nitrate and nitrite in some area ,most studies considered that ammonia very toxic agent to the aquatic life especially when present at high level, it is an important indicator of fecal and chemical pollution in water [3].Nitrate and nitrite are highly soluble in water, a major routes of this agents in rivers are municipal ,industrial ,waste water and septic tanks, our study suggested that the major that waste products and medical discharges is major sources of water pollution[4].

On study by Ibrahim etal. [14] to estimation validity of Tigris River Water, they revealed that temperature, pH and BOD was within the limits recommended by Environmental Protection Agency standards in all areas, this results was in agreement with our study

The present study also documented increasing in the concentration of Pb and Cd in some water samples of the river, heavy metals are most toxic agent to the living organisms, the toxicity of these elements due to their ability to cause oxidative damage to living tissues of fish and other living organisms [15]. It can cause liver disorders due to their active metabolites and free radicals especially when binds covalently to the macromolecules and induced peroxidative degeneration of the lipid membrane of endoplasmic reticulum of the cells .Organs such as gills and liver have been identified as the storage sites of heavy metals. [16]

Many macropathological and histological alterations was observed in gills, liver and intestine of some fish selected from some areas of the river. Histological investigations may therefore

**Physiochemical and histological studies on the effect of some
pollutants on fish and water of El-Garraaf river**

PhD*Amany Mohammed Jasim,

be an effective tool to determine the health of fish populations, hence reflecting the health of an entire aquatic ecosystem. The description and assessment of histological changes in different organs represent a very sensitive and crucial parameter in determining cellular changes that occur in target organs, such as the gills, liver, intestine and gonads [17].

Gills showed many pathological alterations, this may be due to its high sensitivity to pollutants action [18]. Gills comprise a multifunctional organ that play a major role in the regulating the exchange of salt and water, respiration, and acid-base regulation, they are simply affected by contaminants. Histologically, there is only a thin wall between blood and water in the gill which is not only essential for facilitation of the gas exchanges but also exposes the gills to different pollutants that can affect the gills by the low concentration environmental contaminants [18].

Various pathological alterations in liver of some fish studied represented by haemorrhage with intravascular haemolysis of some red blood cells as well as presence of necrosis, histopathological findings of intestine of some fish also recorded degenerative and necrotic area of some lining mucosal epithelium. Many histopathological changes were reported by [19] in liver of fish (*C. gariepinus*) collected from different sites in Sitnica river included loss of cellular architecture of liver, vacuolar degeneration, pycnotic nuclei and focal areas of necrosis of the hepatocytes and dilation of the central vein accompanied by blood congestion was detected they decided that Sitnica river is a polluted river by industrial and urban discharge of liquid waste products.

Conclusions

1-El-Garaaf is a polluted river mainly by hospital discharge and waste products, area of the river located besides the hospital was the highest polluted than the others.

2-Study the macropathology and histopathology of gills, liver, gonads and intestine of fish is a good indicator for detection of chemical and heavy metal accumulation.

Physiochemical and histological studies on the effect of some
pollutants on fish and water of El-Garraf river

PhD*Amany Mohammed Jasim,

Recommendations

- 1- Wastes and hospitals discharge must treat well before discharging to the natural water sources to avoid the toxic effects on the aquatic life.
- 2-Legal actions need to be taken in order to prevent environmental pollution on rivers
- 3-Great care attention must be given to the medical waste products and the method of treatment
- 4-Considerable attention and regular checks should be made to fresh water and the level of chemical and heavy metals in order to safeguard public health.

References

1. Vinodhini,R. and Narayanan, M. (2009) .Heavy metal induced histopathological alteration in the selected organs of the *cyprinus carpio* L. (common carp). Int. J. Environ.Res., 3(1): 95-100.
2. Mc Glashan, D.J.; Hughies J.M.(2001). Genetic evidence for historical continuity between populations of the Australian freshwater fish *Craterocephalus stercusmuscarum* (Atherinidae) east and west of the Great Diving Range. J. Fish Biol. 59, 55–67
3. Mohammad, M.; Samira, S and Faryal, A (2013) Assessment of Drinking Water Quality and its Impact on Residents Health in Bahawalpur City Inter. J.Hum. and Soc. Sci. Vol. 3 No. 15;
4. Hill ,M.J (1991) . Nitrate and nitrite in food and water In: Ellits Horwood New York , USA pp 114-121
5. Goldman, C.R. and Horne, A (1983) assessment of BOD in fresh water McGraw-Hill USA pp 267
6. Dimari, G. A.; Abdulkarim, F. I.; Akan, J. C. and Garba, S.T.(2008): Metal concentrations in Tissues of Tilapia galier, Clarias lazera, and Osteoglosidae caught from Alau Dam, Maiduguri, Borno State, Nigeria. Amer J. Envir. Sci. 4 (4): 473 – 379.
7. Vinodhini, R. and Narayanan, M. (2008). Accumulation of heavy metals in organs of fresh water fish cyprinus (common carp) Int. J. Envir. Sci.Tech. 5(2):174-182

**Physiochemical and histological studies on the effect of some
pollutants on fish and water of El-Garraf river**

PhD*Amany Mohammed Jasim,

8. Harvey, S(1975) Heavy metals. In: Pharmacological Basis of Therapeutics 5th ed. Goodman L.S.and Gilman A. (ed). Macmillan. New York. Pp 924-94
9. APHA.(1998) Standard Methods for the Examination of Water and Wastewater. 20th Edition, American Public Health Association , Washington pp138
10. Varma, A.(2010). Handbook of Atomic Absorption Analysis. Vol. I. CRC Press, Boca Raton pp 231-236
11. Bancroft, J.D.; Cook, H.C.; Stirling, R.W. and Turner, D.R. (1994). Manual of histological techniques and their diagnostic application. 2nd Ed. Longman group U.K pp. 241- 245
12. EPA. 1986. Ambient water quality criteria . EPA/ 440/ 5-84-002. Office of Water regulations and standards. USEPA. Washington, Dc.1986.
13. World Health Organization (2003). Revision of WHO Guidelines for water quality of rivers. WHO. Geneva
14. Ibrahim, I.A Ismaeil M.I and. Ibrahim Y. A(2013) Estimation of validity Tigris River Water for Swimming in Baghdad City Advan Physi. Theo. Appli. 18(2) :13-21
15. Al-Abied,M.M (2010).Solid waste management of hospitals in Baghdad city case study of Baghdad Teaching and Al-Mansoor hospitals Msc.thesis coll.Engineering Al-Mustansiria Univ.
16. Lygren, B. K.; Hamre and Waagboe, R. (1999). Effects of Dietary Pro- and Antioxidants on Some Protective Mechanisms and Health Parameters in Atlantic Salmon. J. Aquat. Anim. Health, 11: 211-221.
17. Dutta H.M.(1996) A composite approach for evaluation of the effects of pesticides on fish. In: Fish morphology .Science Publishers, India pp 45-51.
18. Saenphet S.;Thaworn ,W.; Saenphet, K. (2009).Histopathological alterations of the gills, liver, and kidneys testudineus , fish living in unused libnite Asian. J .Trop. Med .Pub. Health.40, 1121–26
19. Morina V. A.;Gavazaj ,F. K.; Dhurata and Cakaj,F.(2013) Histopathologic Biomarker of Fish Liver as Good Bioindicator of Water Pollution in Sitnica River, Kosovo Glob. J. Sci. Res. Agri. Vet. Vol 13: 33-42