


Resistant Dermatophytosis, the Causative Species, and Treatment

Shahad Khudhair Khalaf  (MSc)¹, Anaam Fuad Hussain (FIBMS/FM)², Khudhair Khalaf Al-Kayalli (FIBMS-DV)², Amenah Khudhair Khalaf (MSc)⁴

^{1,3} College of Medicine, University of Diyala, Diyala, Iraq

^{2,4} College of Science, University of Diyala, Diyala, Iraq

Abstract

OPEN ACCESS

Correspondence Address: Shahad khudhair Khalaf

College of Medicine, University of Diyala, Diyala, Iraq

Email: shahadkhudaier@gmail.com

Copyright: ©Authors, 2023, College of Medicine, University of Diyala. This is an open access article under the [CC BY 4.0](https://creativecommons.org/licenses/by/4.0/) license

(<http://creativecommons.org/licenses/by/4.0/>)

Website:

<https://djm.uodiyala.edu.iq/index.php/djm>

Received: 13 November 2022

Accepted: 11 December 2022

Published: 30 June 2023

Background: Dermatophytosis was a fungal infection caused by molds (dermatophytes). Dermatophytes are a group of closely related filamentous fungi able to damage and utilize keratin found in the skin, hair, and nails.

Objective: To isolate the species which cause resistant dermatophytosis, and clinical types of tinea, as well as to assess the response to different antifungal therapies.

Patients and Methods: Ninety-two patients with different clinical types of tinea infections (ringworm) were seen in a private clinic in Baquba city for the period from May 2021 to December 2021, they were (42) females and (50) males, their ages ranged from (7-70) years with a mean age of (27.57±8) years. All patients were diagnosed clinically as ringworm and supported by isolation of the species from samples either by direct examination of samples or cultures on Sabouraud media, and the patients were treated by combination therapy of systemic and topical terbinafine and systemic azole (itraconazole capsules) for (1-3) months.

Results: All patients complained of widespread and concomitant tinea. The most common causative dermatophytes species were *Epidermophyton floccosum* (44%) and *Trichophyton rubrum* (22%), less commonly *Microsporum audouinii* (9.8%), and the others as in Table (1). The most common clinical type was *tinea pedis* (29.3%) then *tinea cruris* (26.1%), *tinea corporis* (22.8%), and *tinea unguis* (20.7%) as in Table (2).

All patients were cured on combination therapy of systemic (terbinafine and itraconazole) and topical (terbinafine). Five patients (5.4%) showed relapses of disease after discontinuation of therapy and retreated by the same method.

Conclusion: *Epidermophyton floccosum* and *Trichophyton rubrum* were the most common cause of resistant tinea. Terbinafine and itraconazole were good therapeutic options for the treatment of resistant tinea.

Keywords: Tinea, Dermatophytes, Terbinafine, Itraconazole

Introduction

Dermatophytosis is a group of fungal infections caused by molds (dermatophytes) [1]. A range of infections ranging from limited skin, subcutaneous to disseminated

and may be fatal infection, variable according to the defense immunity of the host [2]. Dermatophytes are a group of pathogenic, not-opportunistic fungi, which need the

breakdown of keratin of the skin, hair, and nails to supply nutrition for survival and production of lytic enzymes (proteases and lipases) which allows fungal colonization and induction of infection in the individuals [3,4]. Dermatophytes are classified according to the source into Anthropophilic, Zoophilic, and Geophilic. Anthropophilic usually enhances chronic resistant infections with a minimal inflammatory response (e.g. *Trichophyton tonsurans*) [4], which is opposite to severe inflammation induced by Zoophilic type (e.g. *Arthroderma benhamiae* M. canis) [5]. The development of resistant dermatophytes against different antifungal therapy may result from defects in cellular immune response and production of pro-inflammatory (IL2, IL6, and IL8) rather than anti-inflammatory (IL4, IL10, and IL11) interleukins [6].

The most common dermatophytes which liable to develop resistance against systemic antifungals are *Trichophyton rubrum*, *T. interdigital*, and *T. mentagrophytes* [7,8]. Widespread use of topical therapy, containing a combination of antibacterial, antifungal, and steroids or topical potent steroids (like Clobetasol dipropionate) is responsible for the development of resistance dermatophyte or relapsing typical and widespread infections [9-12]. The resistant dermatophytosis is diagnosed clinically and supported or confirmed both in vivo and in vitro by either susceptibility testing (high MIC) or through molecular study (resistance mutation) [12-16].

The clinical criteria which are useful as an indicator of multidrug resistance and modified dermatophytosis are 1. widespread infection previously treated with multiple

regimens. 2. Presence of concomitant infections such as tinea corporis, cruris, and faciei, or localized tinea not cleared by normal antifungal regimens therapy [17,18]. many studies deal with resistant dermatophytosis, and combination therapies of (Terbinafine, Azole, And Griseofulvin) are used [19].

The present study aimed to isolate and identify the species of dermatophytes that cause resistant dermatophytosis (tinea), the clinical types of tinea, and how to treat these infections.

Patients and Methods

A total number of (92) patients with different clinical types of tinea (ringworm) infections, were seen and examined in a private clinic in Baquba city, they were (42) females and (50) males, and their ages ranged from (7-70) years, for the period from May 2021 to December 2021. They complained of skin lesions of different sizes and different sites of the body, for (1-12) month's duration of lesion appearance, the lesions were diagnosed clinically by a specialist physician as dermatophytosis and supported by isolation of dermatophytes by culture and study of microconidia by using direct KOH examination.

All patients were interrogated regarding their age, sex, occupation, marital status, residence, family history, duration of the lesions and medical therapies. All patients were either misdiagnosed and treated by topical corticosteroids or treated by topical and systemic antifungals of bad quality. Most of the patients had a family history of the same lesions, affecting more than one member, particularly the partners.

The clinical diagnosis of tinea was supported and confirmed by isolation of the dermatophytes, either by direct examination or culturing of scrubbing samples, (92) samples were taken from the patients and examined as follows:

Direct examination

Nail clippings and skin scrubs were exposed to direct inspection by putting the sample on a clean glass slide and adding drops of 30% KOH, then covering the specimen with a cover slide and leaving the slide for (30) minutes for the nail clips and directly examined for skin scrubs then for the presence of fungal hyphae [20].

Indirect examination (Culture of specimens)

Specimens of nail clipping and skin fragments and hair were cultured on Sabouraud Dextrose Agar (SDA) plates at pH 6.5, the plates (triplicate) were incubated at 28°C for 7-14 days, with daily examination and observation.

Identification of the dermatophytes

According to [21] the bellow criteria were taken into consideration during identification:

- Colony morphology (color and consistency).
- Reverse color (color changes with age).
- Microscopic characteristics (microconidia and macroconidia, their size, arrangement, shape, and conidial ontogeny).

The presence of growth was seen favorably. Colony morphology on medium, colony microscopic features and other pertinent biochemical tests were carried out for further assessment and dermatophyte species detection. The shape and arrangement of the spores were examined microscopically.

Growth on Potato Dextrose Agar (PDA) Medium

This test was used to differentiate between *T. mentagrophytes* and *T. rubrum*, according to the ability to produce red color on the reverse side of the plates with PDA medium. The fungal inoculum was taken from the colony edge and put in the center of the plates, and then the plates were incubated at 28°C and examined after 14 days for the observation of media color [22].

All patients were treated with topical terbinafine cream three times daily, terbinafine tablets (250 mg) orally once daily and itraconazole capsules (100 mg) twice daily for one to three months according to the response.

Statistical Analysis

The data were analyzed using numbers, and percent. Frequency and also demographic data were analyzed by descriptive statistics, and quantitative data were expressed as mean \pm standard deviation of the mean (SD).

Results

Ninety-two patients with different clinical types of dermatophytosis were seen and examined in a private clinic in Baquba City for the period from the 1st of May 2021 to the 12th of December 2021. They were (42) females and (50) males with ages ranged from (7-70) years and a mean (27.57 \pm 8) years.

All patients had widespread ringworm and concomitant infection (more than one clinical type). Some patients had tinea corporis, cruris, and faciei, others had tinea corporis, cruris, and pedis, while some patients had tinea corporis, unguis, and cruris, as shown in Table (1). Clinically all patients had a widespread infection and either modified by

topical corticosteroid therapy or by insufficient antifungal therapy. Also, all patients had more than one member of the family was infected, and the patient's residents from all cities of Diyala Province.

The clinical diagnosis was supported and confirmed by the isolation of dermatophytes from scrubbing off the lesions either by microscopical examination or by culturing, and which give the following results as shown in Table (1), (21) patients infected by *T. rubrum*, (41) by *E. floccosum*, (9) by *M. audouinii*, (6) by *T. mentagrophyte var-mentagrophyte*, (1) by *T. interdigital*, (6) *M. canis*, (1) by *T. tonsurance*, (1) by *T. schoenlenei*, and (6) caused by other species like *Aspergillus* and *Penicillium*.

According to the site of infection as shown in Table(2), (3) patients had tinea faciei, (1) caused by *E. floccosum*, (1) by *T. mentagrophyte var-mentagrophyte*, and (1)

by *M. audouinii*, (21) patients had tinea corporis, (24) had tinea cruris, (2) had tinea capitis, (19) had tinea unguim (*Onychomycosis*), (27) had tinea pedis, (1) had tinea barbae. Most patients had a widespread infection, especially tinea corporis and may be concomitant with other types, particularly with tinea faciei, cruris, unguium, and capitis.

For most patients with concomitant infection, the isolate showed *T. rubrum*, *T. mentagrophytes*, and *M. audouinii*, and for those with tinea pedis, most of them were infected by *E. floccosum*.

Flow up of therapy for one to three months, all patients showed clearance of the ringworm, and five patients (4.6%) showed relapses of the disease after discontinuation of therapy, and another course of therapy was started.

Table (1): Number of patients according to the species of dermatophytes

Species	No. of Patients	Percentage %
<i>Epidermophyton floccosum</i>	41	44%
<i>Trichophyton rubrum</i>	21	22%
<i>Microsporum audouinii</i>	9	9.8%
<i>Microsporum canis</i>	6	6.5%
<i>Trichophyton mentagrophyte var-mentagrophyte</i>	6	6.5%
<i>Trichophyton mentagrophyte var-interdigitale</i>	1	1.1%
<i>Trichophyton tonsurance</i>	1	1.1%
<i>Trichophyton schoenlenei</i>	1	1.1%
Others	6	6.5%
Total	92	100%

Table (2): Type of infection and the causative species

Type of infection	No. & %	T.tons.	T. rubrum	T. ment.	M. audio.	M. canis	T. interd.	E. flocc.	others
		T.scho.							
Tinea capitis	(2) 2.2%	1 tons. 1 scho.							
Tinea faciei	(3) 3.2%			1	1			1	
Tinea corporis	(21) 22.8%		12	5	4				
Tinea cruris	(24) 26.1 %				1	9		14	
Tinea unguium	(19) 20.7 %							13	4
Tinea pedis	(27) 29.3%		8				1	13	2
Tinea barbae	(1) 1.1 %		1						
Total	(92) 100%	2	21	6	6	9	1	41	6

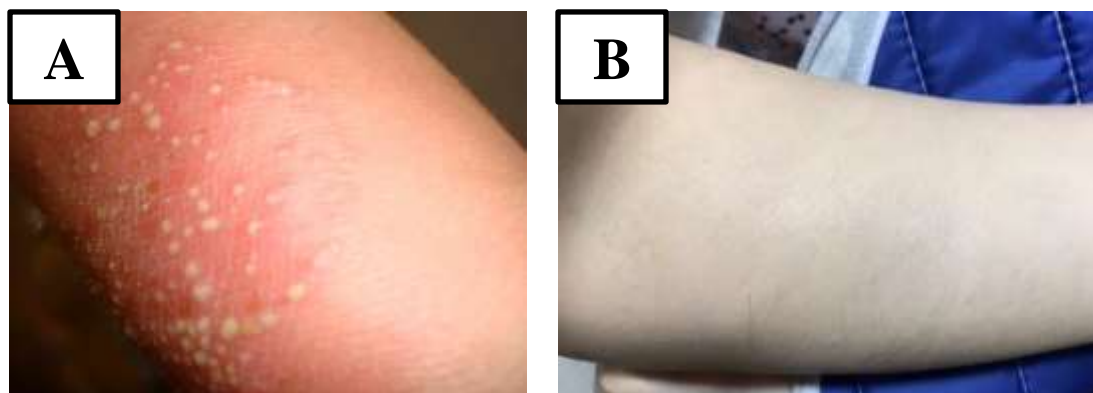


Figure (1): Tinea corporis. A: before treatment, B: after one month of treatment

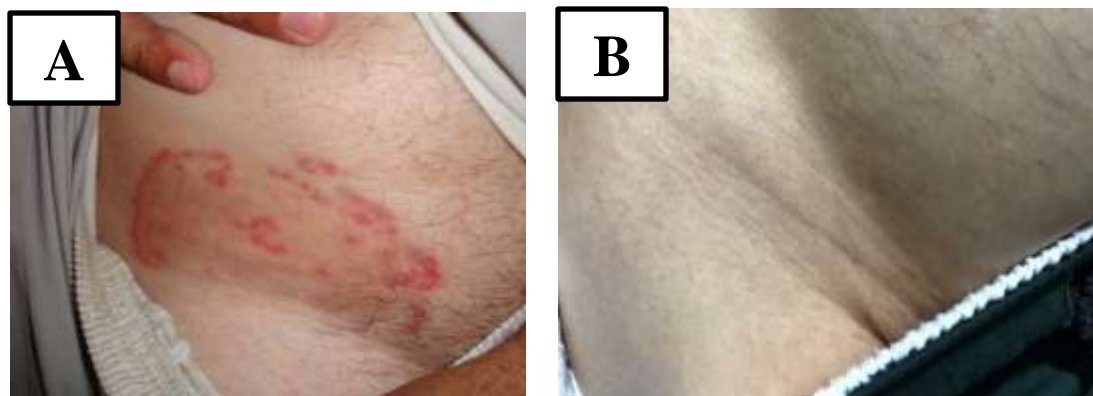


Figure (2): Tinea corporis and tinea cruris. (A): before treatment, (B): after two months of treatment

Discussion

Fungal infections were a common disease in Iraq, both dermatophytes and candidiasis. In this study, 100 patients were included, and most of them have different types of dermatophytosis, which was concordant with other studies [5]. In our study, the development of resistant dermatophytosis appeared as a result of either using a topical potent corticosteroid (Clobetazol diprobanol) or using topical azole antifungal of bad quality or the insufficient duration which results in the emergence of resistant dermatophyte, which is also similar to other studies [9-12,23].

Clinically our study showed that dermatophytosis was a widespread infection and in most of the patients was concomitant, which means the presence of tinea corporis, cruris, faciei, and sometimes tinea pedis or unguium, which also go with other studies [17,18].

Eighty patients (80%) showed a positive family history of more than one member, especially the partners, this indicates that the tinea was contagious and the species of dermatophyte which cause dermatophytosis were anthropophilic in origin and this was supported by isolation of the *T. rubrum* from (21) patients (21%), *M. audouinii* from (9) patients (9%), and *E. floccosum* from (41) patients (41%) of samples these were anthropophilic, which agree with other studies of first groups [1,24] and different from the second and third groups [7,8].

Also regarding the species of dermatophyte which developed resistance in our study were approximately similar to that seen in different countries, (6%) *Trichophyton Spp.*, (29%)

Microsporum spp. and (2%) *Epidermophyton floccosum* but with different percentage [8]. Also, the type of therapy was similar in our study and other different studies [19,24], but the clearance was better in our study.

Conclusions

Epidermophyton floccosum and *Trichophyton rubrum* were the most common cause of resistance dermatophytosis. Tinea pedis was the most common clinical type of infection. The most common cause of the development of resistance was a rowing use of topical corticosteroids or bad-quality of antifungal therapy. Oral terbinafine and itraconazole were good options for the treatment of resistant cases of dermatophytosis in combination with topical terbinafine cream.

Recommendations

We recommend that you see a specialist doctor if symptoms of the aforementioned disease appear, as soon as possible, to take the necessary treatment in the right way, and to avoid taking steroids randomly.

Source of funding: The current study was funded by our charges with no any other funding sources elsewhere.

Ethical clearance: Ethical approval was obtained from the College of Medicine / University of Diyala ethical committee for this study.

Conflict of interest: Nil

References

- [1] Martinez-Rossi NM, Bitencourt TA, Peres NTA, Lang EAS, Gomes E V, Quaresimin NR, et al. Dermatophyte resistance to antifungal drugs: mechanisms and prospectus. *Front Microbiol.* 2018; 9: 1108.

- [2] Kohler JR, Hube B, Puccia R, Casadevall A, Perfect JR. Fungi that infect humans. *Microbiol. Spectr.* 5: FUNK-0014-2016. doi: 10.1128/microbiolspec. FUNK-0014-2016; 2017.
- [3] Havlickova B, Czaika VA, Friedrich M. Epidemiological trends in skin mycoses worldwide. *Mycoses.* 2008; 51: 2–15.
- [4] Hube B, Hay R, Brasch J, Veraldi S, Schaller M. Dermatophytes and inflammation: The adaptive balance between growth, damage, and survival. *J Mycol Med.* 2015; 25(1): e44–58.
- [5] Martinez-Rossi NM, Peres NTA, Rossi A. Pathogenesis of dermatophytosis: sensing the host tissue. *Mycopathologia.* 2017; 182(1–2): 215–27.
- [6] Gupta AK, Kohli Y. In vitro susceptibility testing of ciclopirox, terbinafine, ketoconazole and itraconazole against dermatophytes and nondermatophytes, and in vitro evaluation of combination antifungal activity. *Br J Dermatol.* 2003; 149(2): 296–305.
- [7] de Hoog GS, Dukik K, Monod M, Packeu A, Stubbe D, Hendrickx M, et al. Toward a novel multilocus phylogenetic taxonomy for the dermatophytes. *Mycopathologia.* 2017; 182(1–2): 5–31.
- [8] Uhrlaß S, Schroedl W, Mehlhorn C, Krüger C, Hubka V, Maier T, et al. Molecular epidemiology of *Trichophyton quinckeanum*—a zoophilic dermatophyte on the rise. *JDDG J der Dtsch Dermatologischen Gesellschaft.* 2018; 16(1): 21–32.
- [9] Nenoff P, Verma SB, Vasani R, Burmester A, Hipler U, Wittig F, et al. The current Indian epidemic of superficial dermatophytosis due to *Trichophyton mentagrophytes*—A molecular study. *Mycoses.* 2019; 62(4): 336–56.
- [10] Ebert A, Monod M, Salamin K, Burmester A, Uhrlaß S, Wiegand C, et al. Alarming India-wide phenomenon of antifungal resistance in dermatophytes: A multicentre study. *Mycoses.* 2020; 63(7): 717–28.
- [11] Shenoy MM, Jayaraman J. Epidemic of difficult-to-treat tinea in India: Current scenario, culprits, and curbing strategies. *Arch Med Heal Sci.* 2019; 7(1): 112.
- [12] Dogra S, Shaw D, Rudramurthy SM. Antifungal drug susceptibility testing of dermatophytes: Laboratory findings to clinical implications. *Indian Dermatol Online J.* 2019; 10(3): 225.
- [13] Saunte DML, Hare RK, Jørgensen KM, Jørgensen R, Deleuran M, Zachariae CO, et al. Emerging terbinafine resistance in *Trichophyton*: clinical characteristics, squalene epoxidase gene mutations, and a reliable EUCAST method for detection. *Antimicrob Agents Chemother.* 2019; 63(10): e01126-19.
- [14] Süß A, Uhrlass S, Ludes A, Verma SB, Monod M, Krueger C, et al. Extensive tinea corporis due to a terbinafine-resistant *Trichophyton mentagrophytes* isolate of the Indian genotype in a young infant from Bahrain in Germany. *Hautarzt.* 2019; 70(11): 888–96.
- [15] Nenoff P, Verma SB, Ebert A, Süß A, Fischer E, Auerswald E, et al. Spread of Terbinafine-Resistant *Trichophyton mentagrophytes* Type VIII (India) in Germany—“The Tip of the Iceberg?” *J Fungi.* 2020; 6(4): 207.
- [16] Sacheli R, Harag S, Dehavay F, Evrard S, Rousseaux D, Adjetey A, et al. Belgian

- national survey on tinea capitis: Epidemiological considerations and highlight of terbinafine-resistant *T. mentagrophytes* with a mutation on *SQL* gene. *J Fungi*. 2020; 6(4): 195.
- [17] Hiruma J, Kitagawa H, Noguchi H, Kano R, Hiruma M, Kamata H, et al. Terbinafine-resistant strain of *Trichophyton interdigitale* strain isolated from a tinea pedis patient. *J Dermatol*. 2019; 46(4): 351–3.
- [18] Fattahi A, Shirvani F, Ayatollahi A, Rezaei-Matehkolaei A, Badali H, Lotfali E, et al. Multidrug-resistant *Trichophyton mentagrophytes* genotype VIII in an Iranian family with generalized dermatophytosis: report of four cases and review of literature. *Int J Dermatol*. 2021; 60(6): 686–92.
- [19] Brescini L, Fioriti S, Morroni G, Barchiesi F. Antifungal combinations in dermatophytes. *J Fungi*. 2021; 7(9): 727.
- [20] Kwon-Chung KJ, Bennett JE. Medical mycology. *Rev Inst Med Trop Sao Paulo*. 1992; 34(6): 504.
- [21] M De La Maza L. Color Atlas of diagnostic microbiology. Mosby; 1997.
- [22] Collee JG, Fraser AG, Marmion BP, Simmons A. Mackie & MacCartney Practical Medical Microbiology 14th Ed., 838–841. Churchill Living Stone, New York, Edinburgh, London. 1996.
- [23] Verma SB, Zouboulis C. Indian irrational skin creams and steroid-modified dermatophytosis-an unholy nexus and alarming situation. *J Eur Acad Dermatology Venereol JEADV*. 2018; 32(11): e426–7.
- [24] Shen JJ, Arendrup MC, Verma S, Saunte DML. The emerging terbinafine-resistant *Trichophyton* epidemic: What Is the role of antifungal susceptibility testing? *Dermatology*. 2022; 238(1): 60–79.
- [25] Khalifa E. Sharquie , Raed I. Jbbar . New multiple therapy of resistant and relapsing dermatophyte infections during epidemic status. *JPAD*. 2022; 32(3): 464-471.

الفطريات الجلدية المقاومة، الأنواع المسببة والعلاج

شهد خضير خلف^١، انعام فؤاد حسين^٢، خضير خلف ابراهيم^٣، امينة خضير خلف^٤

المخلص

خلفية الدراسة: الفطريات الجلدية هي عدوى فطرية تسببها الفطريات (الفطريات الجلدية) وهي مجموعة من الفطريات الخيطية القادرة على إتلاف الجلد والشعر والأظافر واستخدام الكيراتين الموجود فيها. **اهداف الدراسة:** لعزل الأنواع التي تسبب الإصابات الجلدية مقاومة للعلاج ، وأنواع المرضية المسببة لداء السعفة ، وكذلك تقييم الاستجابة لمختلف العلاجات المضادة للفطريات.

المرضى والطرائق: تم فحص ٩٢ مريضاً يعانون من أنواع سريرية مختلفة من عدوى السعفة (القوباء الحلقية) في عيادة خاصة في مدينة بعقوبة للفترة من مايو ٢٠٢١ إلى ديسمبر ٢٠٢١ ، كانوا (٤٢) أنثى و (٥٠) ذكراً. تراوحت الأعمار من (٧-٧٠) سنة بمتوسط عمر (٨ ± ٢٧,٥٧) سنوات. تم تشخيص جميع المرضى سريريًا على أنهم مصابون بالسعفة وتم تأكيد الإصابة بعزل الأنواع من العينات إما عن طريق الفحص المباشر للعينات أو الزرع على وسط سابورود ، وتم علاج المرضى من خلال العلاج المركب من تيربينافين الجهازى والموضعي والأزول الجهازى (كيسولات إيتراكونازول) لمدة (٣-١) أشهر. **النتائج:** كانوا جميع المرضى يعانون من سعفة (القوباء الحلقية) منتشرة على مناطق مختلفة من الجسم، وكانت أكثر أنواع الفطريات الجلدية المسببة شيوعاً كانت (*Epidermophyton floccosum* (٤١%) و (*Trichophyton rubrum* (٢١%) ، والأقل شيوعاً (٩%) *Microsporum audouinii* ، والأنواع الأخرى كما في الجدول (١). كان النوع السريري الأكثر شيوعاً هو سعفة القدم (٢٧%) ثم سعفة الأظافر (٢٤%) والسعفة الجسدية (٢١%) وسعفة الأظافر (١٩%) كما في الجدول (٢). تم علاج جميع المرضى باستخدام العلاج المركب (تيربينافين وإيتراكونازول) والموضعي (تيربينافين). أظهر خمسة مرضى (٤,٦%) انتكاسات للمرض بعد التوقف عن العلاج وتم إعادة العلاج بنفس الطريقة.

الاستنتاجات: كانت الإصابة بالأنواع *Epidermophyton floccosum* و *Trichophyton rubrum* هما السببان الأكثر شيوعاً للإصابة بداء السعفة المقاومة، و كان *Terbinafine* و *itraconazole* من الخيارات العلاجية الجيدة لعلاج السعفة المقاومة.

الكلمات المفتاحية: السعفة، فطريات جلدية ، تيربينافين ، إيتراكونازول

البريد الإلكتروني: shahadkhudaier@gmail.com

تاريخ استلام البحث: ١٣ تشرين الثاني ٢٠٢٢

تاريخ قبول البحث: ١١ كانون الاول ٢٠٢٢

^{٣,١} كلية الطب - جامعة ديالى - ديالى - العراق

^{٤,٢} كلية العلوم - جامعة ديالى - ديالى - العراق