

Fine Needle Aspiration Versus Open Biopsy for Testicular Sperm Recovery in Infertile Azoospermic Patients

Salah A Ali¹ and Suhel Al-Najjar²

Abstract

Background and Objectives: This study aimed to develop a predictive model for sperm retrieval rate (SRR) sperm recovery by testicular fine-needle aspiration (TESA) & compare with (SRR) obtained by per cutaneous open biopsy sperm aspiration (PSA) correlating with hormonal parameters.

Materials and Methods: This is a prospective study for sample obtained from 45 male patients during the period from January 2011 to March 2012. Clinical, paraclinical, and histological information of patients were gathered. All patients underwent both TESA and PSA in a single operation. Predictors of SRR by TESA were identified comparing with predictive outcome of PSA.

Statistical Analysis Used: Categorical and continuous variables were compared using independent t test and -chi-square test. Logistic regression model was applied to develop a predictive model for SRR by TESA & PSA outcome.

Results: Sperm retrieval rate for TESA and PSA was 42.2% and 48.8%, respectively ($P = 0.03$). Regarding age group is more common in 4th (50.3%), while 3rd & 5th decades each of them (20%). The duration of infertility were variable ranging from (10-20) years. Testis volume, luteinizing hormone, prolactin, and testosterone did not differ between patients.

Conclusions: Serum FSH and testicular pathology were predictors of SRR by TESA. Patients with FSH < 23 IU/l and/or testicular pathology of hypospermatogenesis had comparable SRR by TESA versus PSA.

Keywords: Follicular-stimulating hormone, sperm recovery rate, testicular fine-needle aspiration, testicular open biopsy, hypospermatogenesis.

¹ Hawler Centre for invitro fertilization in Erbil - Iraq.

² Hawler Centre for invitro fertilization in Erbil - Iraq.

Introduction

In the normal male reproductive tract, sperm exiting in the testis have minimal motility and limited egg fertilizing capacity. Sperm acquire the potential for improved motility and fertilizing ability during epididymal transit. So, in the unobstructed epididymis, sperm of optimal quality (as evaluated by percent motile cells) are found in the most distal epididymis[1]. The

obstructed epididymis shows the opposite pattern of sperm quality: optimal sperm quality in the proximal epididymis and very poor quality in the most distal segments. This finding of "inverted motility" is expected in the obstructed male reproductive tract since sperm production continues in the testis and reabsorption of those sperm is an active process in the most distal regions of the system. The most distal obstructed epididymis tends to contain dilated yellow

tubules that are packed with macrophages reabsorbing old, degenerated sperm [2]. Therefore, sperm retrieval should be performed from the proximal obstructed epididymis

Although excisional testicular biopsy is a less invasive surgical technique than microsurgical epididymal sperm aspiration, even less invasive procedures have been proposed for the recovery of either epididymal or testicular spermatozoa [3]. Percutaneous sperm recovery procedures, in particular, are becoming more popular. However, so far the reports on this technique have been merely on a case by case basis and it has not been shown whether ICSI using percutaneous aspirated testicular spermatozoa offers success rates comparable to ICSI with spermatozoa retrieved by the open excisional approach. The present study therefore aimed at comparing the results of ICSI using testicular spermatozoa recovered by an open excisional technique and ICSI using testicular spermatozoa recovered by a percutaneous fine needle aspiration (FNA) technique.

Patients and Methods

In the current study the samples were taken by both methods TESA & PSA from 45 male patients presented with azoospermia to perform in vitro fertilization comparing the outcome from procedures.

Per cutaneous sperm aspiration (PSA) procedures performed by doing a small incision that is well tolerated under local anesthesia. The procedure is performed with the spermatic cord block and sedation. A tunica vaginalis space entered via transverse 1-cm scrotal incision. A self-retaining eye-lid retractor is placed to create a window into the tunica vaginalis space.

The posteriorly located epididymis is rotated into view by gentle traction or placement of 7-0 Prolene traction suture into

the epididymal tunic. Under the operating microscope the epididymal tunic is incised and individual tubule isolated. After careful hemostasis with bipolar cautery, epididymal tubule is incised tangentially with microscissors. Fluid is aspirated with a 24-gauge angiocath sheath attached to a 1.0-ml syringe. About 10 microliters of aspirated fluid is examined under 400X light microscope. Aspiration sites then progress from cauda to caput in order to obtain best quality sperm. Epididymal tubule and tunic are closed with 10-0 and 9-0 nylon sutures respectively. Tunica vaginalis space is closed with 4-0 absorbable suture after irrigation with saline and local anesthetic without epinephrine. Skin edges are reapproximated with 4-0 absorbable suture [4].

The technique of Testicular Fine Needle Aspiration (TESA) of the testis was initially described as a diagnostic procedure in azoospermic men. Subsequently, testicular fine needle aspiration or biopsy for the recovery of spermatozoa has been described. Percutaneous puncture and aspiration of the testis can be performed by using a 22 gauge needle connected to a 20 cc syringe in a Menghini syringe holder [5].

Results

A total of 45 cases of infertile male were included in this study. Both TESA & PSA were performed for them to obtain sperm for purpose of in vitro fertilization.

The age distribution of different cases studied is shown in table (1), the mean age (\pm SD) for cases of infertility was (45) years. Out of 45 cases of infertility, the majority of cases (53.3%) ranged between 31-40 years, and only 3 case (6.7%) was above 50 years old.

Table (1): showing age distribution of patients with infertility & positive results in both procedures.

Age groups(Years)	No of cases & %	Positive with PSA	Positive with TESA
21-30	9(20%)	2	1
31-40	24(53.3%)	9	7
41-50	9(20%)	4	4
Above 50	36.7%)	0	2
Total	45(100%)	15	14

Sperm retrieval rate for TESA and PSA was 42.2% and 48.8%, respectively ($P = 0.03$) which is significant regarding age group, more common in 4th (50.3%) while 3rd & 5th dacades each of them (20%). The duration of infertility were variable ranging from (10-20)years, testis volume, luteinizing hormone, prolactine, and testosterone did not differ between patients with and without mature sperm in TESA samples. Serum

follicular-stimulating hormone (FSH) < 23 IU/l in 53.3% ranging from (6-28) IUI/l with $P = 0.002$) and histology of hypo spermatogenesis was in 30 cases (66.6%) $P < 0.001$) figure (1) which is highly significant & were predictors of SRR by TESA. In patients with FSH < 23 IU/l (53.3%) versus less than 6 IU/l(46.7%) and testicular histology of hypo spermatogenesis 14 cases (33.4%)figure(2).

Table (2): hormonal levels related to age groups.

Age groups(years)	FSH(IU/l)	LH(IU/l)	Testosterone(IU/l)
21-30	23	3-7	3-6
31-40	6,50% 23 50%	4-7	2-6
41-50	17	3.5-6	3-6
Above 50	28	3-5	3-4

Table (3): sperm retrival rates(SRR) in TESA & PSA.

SRR	TESA	PSA
No of cases	19	22
%	42.2	48.8

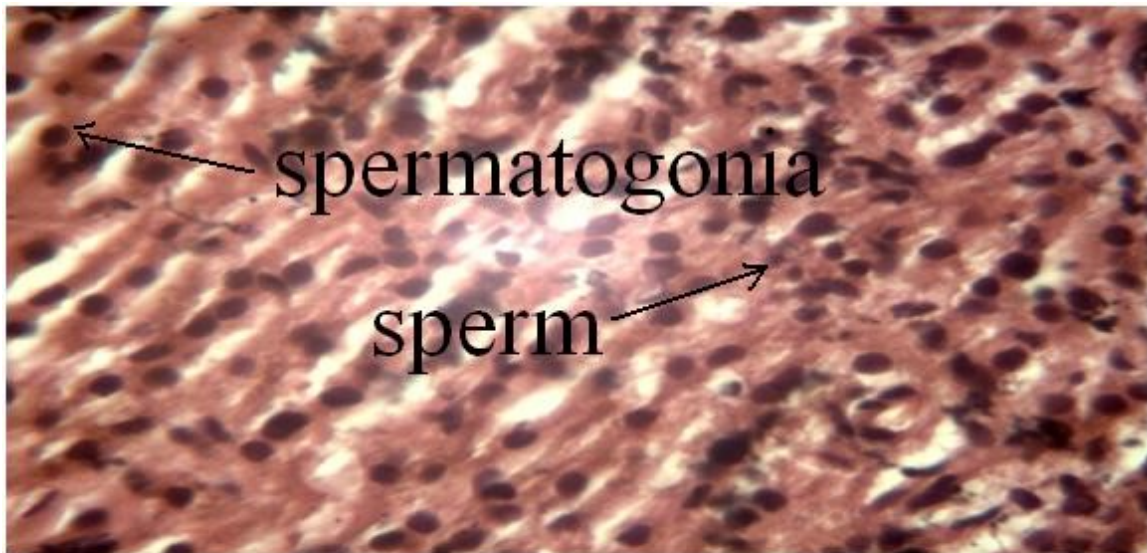

Figure (1): Open Biopsy Hypospermic Testis.

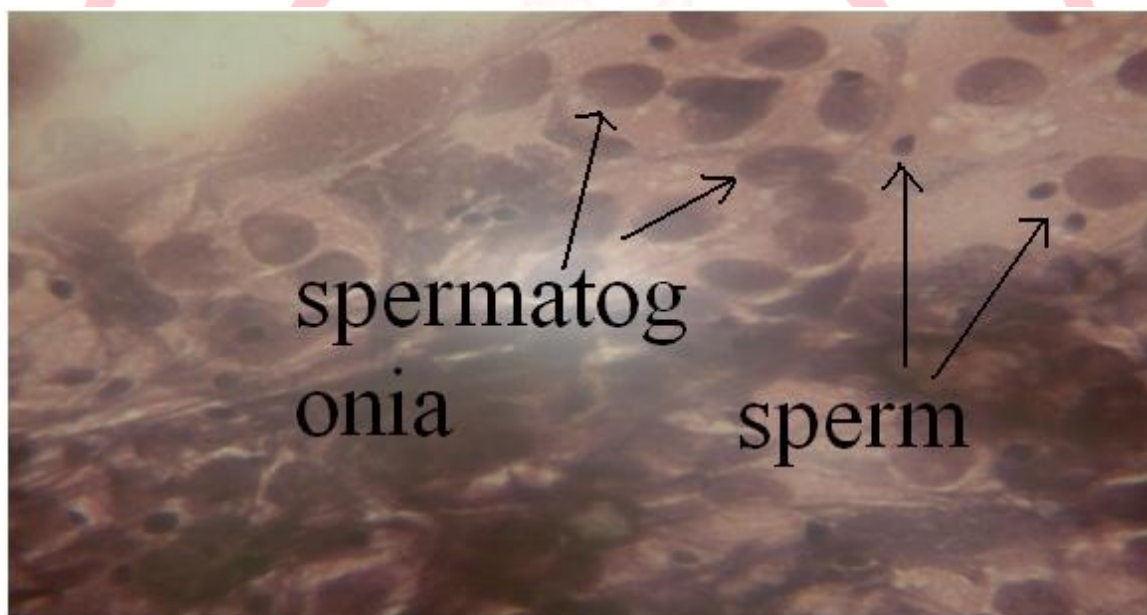


Figure (2): FNA of testis hypospermic testis.

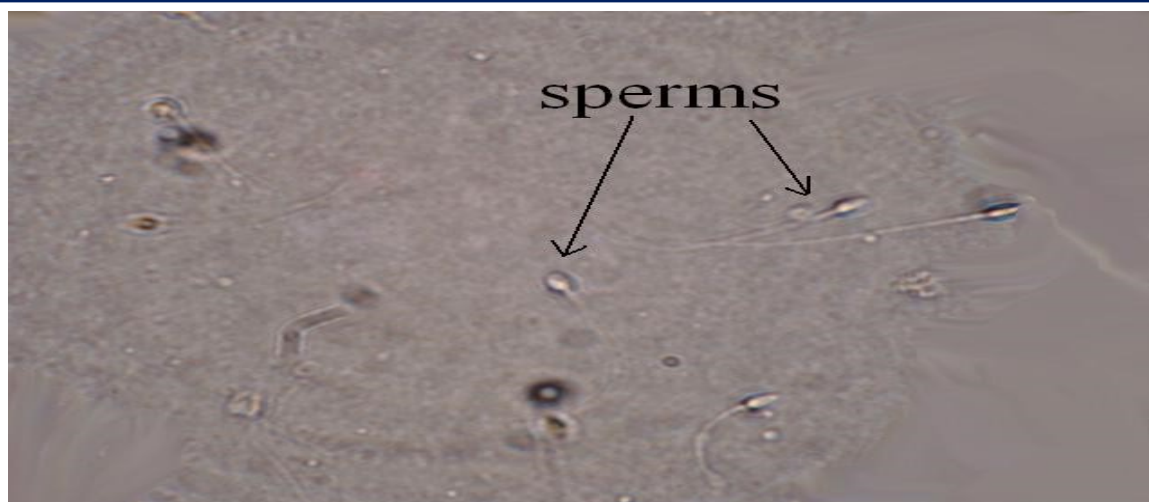

Figure (3): sperm retrievals.

Discussion

In all azoospermic patients with normal spermatogenesis, i.e. patients with so-called obstructive azoospermia, testicular spermatozoa may be recovered by open excisional biopsy [6]. The open excisional biopsy technique is an invasive procedure which may cause discomfort for the patient, even if only taken through a small incision and even after meticulous haemostasis. Percutaneous puncture of the testis using a fine 22-gauge needle is a less invasive procedure which has been used successfully to recover testicular samples for diagnostic purposes. Then this sampling method allows only cytological investigation because it contains only a limited quantity of aspirated testicular cells which may, however, be sufficient in order to establish the diagnosis of normal spermatogenesis [7]. A more invasive fine needle tissue aspiration technique has been reported to recover testicular spermatozoa for ICSI, and pregnancies have been obtained [8]. However, many patients may suffer varying degrees of discomfort during these tissue aspiration procedures, in which a 24-gauge biopsy gun-type needle is used. Others have successfully used a thinner 22-gauge needle [3]. In the present study, we used a fine 22-

gauge needle for testicular aspiration. Although patient comfort was not assessed in the present retrospective study, in our experience patients undergoing percutaneous sperm aspiration tended to report less pain and discomfort once at home than those who had had an open biopsy. The percutaneous sperm aspiration, however, risks of recovering only a few spermatozoa but the testicular tissue is composed of seminiferous tubules which are easily aspirated by special maneuver sufficient amount of sperm can be aspirated. In the present study, we found that although the number of samples taken, i.e. aspirates or biopsies were comparable, significantly fewer spermatozoa were harvested after FNA than after open biopsy. In 19 cases out of 45 FNAs (42.2%), a sufficient number of spermatozoa were recovered to allow ICSI, and in open biopsy 22 out of 45 cases (48.8%) sufficient number of spermatozoa were recovered. The difference is not significant regarding the outcome in TESA 14 pregnancy were take place while in PSA 15 pregnancy were take place which is similar to study did by **Tournaye** [9]. The overall pregnancy rates were 27.5% for FNA- ICSI cycles (14 pregnancies) and

27.5% for excisional biopsy–ICSI cycles (14 pregnancies).

Conclusion

Testicular fine needle aspiration is very good procedure for diagnosis & retrieving of sperms for infertile male with less side effect than open biopsy with producing the same number of pregnancy for infertile couples

References

- [1] Schlegel P, Palermo G, Alkani M., Adler A, Reing A., Cohen J, Tpzewaks Z. Micropuncture retrieval of eoididymal sperm with in vitro fertilization: omportance of in vitro micromanipulation techniques. *Urology* 1995; 46:238
- [2] Craft I, Tsirigotis M, Bennett V, Taratnissi M, Khalifa Y et al. Percutaneous epididymal sperm aspiration and intracytoplasmic sperm injection in the management of infertility due to obstructive azoospermia. *Fertil Steril* 1995; 63:1038
- [3] Lewin, A., Weiss, D.B., Friedler, S. *et al.* Delivery following intracytoplasmic sperm injection of mature sperm cells recovered by testicular fine needle aspiration in a case of hypergonadotrophic azoospermia due to maturation arrest. *Hu Reprod* (1996) 11, 769–773.
- [4] Nudell DM, Conaghan J, Pedersen RA, Givens CR, Schriock ED, Turek PJ. The mini-micro-epididymal sperm aspiration for sperm retrieval: a study of urological outcomes. *Hum.Reprod.* 1998; 13:12601265
- [5] Friedler S, Raziell A, Strassburger D, Soffer Y, Komarovsky D, Ron-El R. Testicular sperm retrieval by percutaneous fine needle sperm aspiration compared with testicular sperm extraction by open biopsy in men with non-obstructive azoospermia. *Hum Repord* 1997; 12:1488-1493
- [6] Tournaye, H, Liu, J, Nagy Z et al. Correlation between testicular histology and outcome after intracytoplasmic sperm

injection using testicular sperm. *Hum. Reprod* 2006; 11, 127–132.

- [7] Foresta, C, Varotto, A and Scandellari, C Assessment of testicular cyology by fine needle aspiration as a diagnostic parameter in the evaluation of the azoospermic subject. *Fertil Steril* 2002; 57, 858–865.
- [8] Bourne H, Watkins W, Speirs A and Gordon Baker, H.W. Pregnancies after intracytoplasmic sperm injection of sperm collected by fine needle biopsy of the testis. *Fertil Steril* 2005; 64, 433–436.
- [9] Herman Tournaye1, Koen C, A, Zsolt N, Andre´ VS and Paul D H *Reproduction* 2008; 13(4):901–904.