

Effects of N-Acetyl Cysteine and/or Selenium on Methionine-Induced Ovary and Uterus Histological Damage and Oxidative Stress in Rats

* Lana S. Al-Alim

** Goran Q. Othman

*** Yasin K. Amin

Abstract

Background: Methionine supplementation is considered as one of the main factors inducing hyperhomocysteinemia, which is thought to stimulate inflammation and increase the risk of vascular diseases.

Aim of study: The purpose of the present study was to determine the effects of selenium, N-acetyl cystein and their combination on certain biochemical parameters and histological structure of ovary and uterus.

Materials and Methods: Four groups (n=6) of female rats were randomly assigned to receive a diet supplement containing (17gm/kg body weight) methionine, while the control group n=6 for each group) were fed standard diet. In group 2, (1gm/kg body weight) N-acetyl cysteine were fed with the methionine diet, while in group 3, (5ppm) selenium was added to the water.

The combinations of all treatments (Methionine, N-acetyl cysteine and selenium) were used in group four. After 5 weeks, all rats were dissected for biochemical tests including determination of reduced glutathione (GSH) and thiobarbituric acid reactive substance (TBARS) in sera, also histological evaluation performed in histological paraffin sections of ovary and uterus.

Results: The data revealed a significant ($P < 0.01$) elevation of TBARS and significant reduction in GSH in methionine treated rats. The histological sections showed reduced of ovarian follicles associated with infiltration of mononuclear inflammatory cells in myometrium of uterus. Significant restoring of TBARS and reduced GSH levels were produced by all NAC, selenium and combination treatments, except for selenium which failed to decrease TBARS significantly. The developmental stages of ovarian follicles similar to control rats were seen in combination group.

Conclusion: This finding explains the oxidative and toxic actions of methionine, and the antioxidant activity of NAC and selenium, also it explains the synergistic therapeutic effects of NAC and selenium combination.

Keywords: Methionine - N-Acetyl cystein - Selenium

* Biology Department/ College of Science/ Salahaddin University/ Erbil / Iraq.

** Medical Lab. Techniques Department / Medical Technical Inst./ Erbil / Iraq.

*** Anatomy and Histology Department/ Hawler Medical University/ Erbil/ Iraq.

Introduction

Methionine (Met) is an essential amino acid which is metabolized to homocysteine (Hcy), a sulfhydryl-containing nonprotein amino acid [1]. Hyperhomocysteinemia (HHcy), which refers to total plasma Hcy above 15 $\mu\text{mol/L}$, is caused by an abnormality in either an enzyme (cystathionine β -synthetase or temperature-sensitive methylenetetrahydrofolate reductase) or a cofactor (folate, vitamin B-12, or vitamin B-6) required for Hcy metabolism [2]. The phenomenon of hyperhomocysteinemia is now suggested to be one of the most important risk factors for cardiovascular and cerebral vascular disorders [3]. It has been suggested that elevated plasma Hcy levels occur in a large proportion of patients with coronary artery disease [4]. Several possible mechanisms for Hcy-induced cardiovascular and cerebral vascular disorders have been proposed, including endothelial dysfunction [5], impaired flow-mediated vasodilation [6], increased proliferation of vascular smooth muscle cells [7], enhanced coagulability [8], and HHcy also induces disturbances in lipid peroxidation and reactive oxygen species (ROS)[9].

The plasma homocysteine concentration is affected by various factors, including genetic, nutritional, physiological, clinical, lifestyle, and drugs [10]. Although, folate, vitamin B-12 and vitamin B-6 are major nutritional determinants of plasma total homocysteine (tHcy) [11]. It was confirmed that some amino acids participate in the metabolism of methionine or homocysteine [12]. It has been found that serine and cystine suppress the enhancement of plasma homocysteine concentration due to a single ingestion of a methionine-supplemented low-protein meal in humans [13]. Another study [14] concluded that in patients with

hyperhomocysteinaemic CAD, folic acid and NAC lowered plasma homocysteine levels and improved endothelial function.

The effects of both treatments in improvement of endothelium-dependent dilation were similar.

In early 1980s, the researchers of indicated that free homocysteine was decreased in the plasma of selenium-deficient animals [15].

They also reported that selenium-deficient animals had decreased concentrations of cysteine and cystathionine in plasma, but no change in plasma methionine concentration [16]. Investigators showed that plasma total homocysteine is markedly reduced by selenium deficiency in Fisher-344 rats [17].

The findings of selenium deficiency decreases the plasma concentrations of cysteine, cystathionine and homocysteine, and increases the concentration of plasma and liver glutathione, strongly suggest that selenium deficiency and supplementation can affect the metabolism of methionine. Therefore, this investigation was designed to confirm the effect of NAC, Selenium and their combination on female rats supplemented with diet containing high amount of methionine.

Materials and Methods

Animals and housing

Thirty adult female albino rats of about 250-300g body weight and 8-10 weeks old were used. The experiment was achieved in the animal house in the Dept. of Biology /College of Science/ University of Salahaddin -Erbil. Animals were housed in plastic cages bedded with wooden chips. During the experimental period six animals were kept in each cage and they were housed under standard laboratory conditions, 12:12 light/dark photoperiod (LD) at 22 ± 2 °C. [18].

Experimental Design

Rats were divided into five groups, each group contains six rats and the methionine supplementations were continued for 5 weeks.

Group 1: Control: The rats of this group were given a standard rat chow and tap water *ad libitum*.

Group 2: Methionine treated rats: The rats of this group supplemented with diet contains (17gm/kg b.w.) or (1.7%) of methionine along the period of study [19].

Group 3: Rats treated with selenium: The rats of this group supplemented with 17mg/kg b.w. of methionine and water containing (5 ppm) of selenium along the period of study [20]

Group 4: Rats treated with NAC: The rats of this group supplemented with 17mg/kg b.w. of methionine and (1g/kg b.w.) of NAC along the period of study [21].

Group 5: Rats treated with both selenium and NAC: The rats of this group supplemented with 17mg/kg b.w. of methionine, (1g/kg b.w.) of NAC and water containing (5 ppm) of selenium along the period of study.

Collection of blood samples

At the end of each experiment, the rats were anesthetized with ketamine hydrochloride (100mg/kg). Blood samples were taken by cardiac puncture into chilled tubes and centrifuged at 3000rpm under 0C for 15 minute(Sony, Ultra low, Japan); at -80C the serum were stored, the rats were dissected for other evaluations and tests [22].

Histological Preparation of Ovaries and Uterus:

Ovaries and uterus samples were removed from the anesthetized animals. All samples were fixed in Bouin's fluid and processed for light microscopy by embedding in paraffin after dehydration and clearing. Six micrometers thick sections were stained by haematoxylin and eosin [25].

Determination of reduce glutathione (GSH)

The level of serum GSH was determined by using Ellman's reagent. The principle is the reaction between the glutathione in serum and Ellman's reagent which gives a color and read at 412 nm by spectrophotometry (UV-Vis Beckman Inc.). In brief, equal volume of serum sample (150 μ l) mixed with 4% sulfosalicylic acid. The mixture centrifuged at 2000 rpm for 5 min..Then 4.5 ml of Ellman's reagent added to 150 μ l of supernatant which we obtained from centrifugation, allowed for 5 min. in room temperature, then scanned spectrophotometry [23].

Determination of serum Thiobarbituric Reactive Substances (TBRS)

The level of serum TBRS was determined spectrophotometrically with a TBA solution. To150 μ l serum sample added the followings: 1ml trichloroacetic acid (TCA) 17.5% and 1ml of 0.66% thiobarbituric acid (TBA) mixed well by vortex, incubated in boiling water for 15 minutes, and then allowed to cool. One ml of 70% TCA was added and let the mixture to stand in room temperature for 20 minutes, centrifuged at 2000 rpm for 15 minutes, and take out the supernatant for scanning spectrophotometrically[24].

Statistical analysis

All data were expressed as means \pm standard error (SE) and statistical analysis was carried out by using statistically software (SPSS version 11.5).Data analysis was made using one-way analysis of variance (ANOVA). The comparisons between groups were done by using Duncan's test. The levels of significance were set at $P < 0.05$ or $P < 0.01$ [26].

Results and Discussion

Effects of methionine on reproductive tissues TBARS and GSH

Statistical analysis revealed a significant elevation ($P < 0.01$) in serum TBARS level with mean value ($3.48 \pm 0.41 \mu\text{mol/ml}$) in methionine treated rat, in comparison to the control rats, which recorded only ($0.85 \pm 0.21 \mu\text{mol/ml}$) as shown in (Figure 2).

While opposite results were observed in GSH level, as it's decreased significantly ($P < 0.01$) in methionine treatment to ($17.57 \pm 1.32 \mu\text{mol/ml}$) as compared to GSH concentration in control rats ($28.4 \pm 1.25 \mu\text{mol/ml}$) (Figure 1). Indeed, the majority of methionine diet toxicity is due to the oxidative action of elevated homocysteine level produced as a metabolite product of methionine. Study results suggest that the oxidative stress resulting from elevated plasma homocysteine stimulates the activation of nuclear factor κB , and consequently increases the expression of the inflammatory factors in vivo [32]. Serum lower GSH [33, 34] and greater TBARS [35, 36] were suggested to be the main markers of oxidative stress and antioxidant depletion in experimentally methionine treated rats.

Histological section of normal ovarian section showed many ovarian follicle at different stages of development Plate (1) and uterus section revealed many uterine glands in endometrium in addition of smooth muscle in myometrium region. While Plate (3) showed ovarian atrophy in addition of reduction in the number of developed follicles, while there were undefined infiltration development stages of inflammatory cells with the presence of pyknotic nuclei. Several observations reported normal histology and correct structural organization and function of the ovaries in elevated serum homocysteine level [27], however Guzman *et al.* [28]

demonstrate a decreased number of developed ovarian follicles in hyperhomocysteinemic cystathionine beta synthase knockout (cbsKO) mice in comparison to wild type mice. When as the uterus showed clear infiltration of inflammatory cells between muscle fiber in the myometrium (Plate 4), whereas plate (2) illustrates the uterus of control rats. A few recent in vitro studies indicate that Hcy affects the expression of some inflammatory factors. Studies reported that Hcy increases the expression of MCP-1, a strong inflammatory mediator, in both human aortic endothelial cells [29] and monocytes [30]. Chronic exposure to Hcy also increases the production of another inflammatory agent, ICAM-1 in endothelial cells [31].

Effects of NAC on methionine treated rats

The antioxidant activity of NAC was obvious in the results, as it can significantly reduce the high level of TBARS which was produced by methionine to about (2.34 ± 0.53) (Figure 1). Also it significantly restored the level of GSH to (21.89 ± 1.16) (Figure 2).

Several studies demonstrate the beneficial actions of NAC in hyperhomocysteinemic animals through its antioxidant potential [37, 38]. NAC is able to modify plasma thiols concentration representing by serum reduced GSH and in particular to reduce homocysteine levels in hyperhomocysteinemia [39].

Histological sections of rat's ovary treated with NAC showed congestion of blood vessels and some ovarian follicles are not well developed (Plate 5). While the uterus showed thickness increase of myometrium and the atrophy of uterine gland (Plate 6).

Effects of Selenium on methionine treated rats

Selenium administration recorded lesser antioxidant actions in comparison to NAC, because it failed to reduce the high TBARS level significantly (2.99 ± 0.28). However,

significant increase was found in GSH level (21.22 ± 0.66). The relation between methionine metabolite and selenium was studied by Angelova *et al.*, (2008) [40] who observed Lower serum selenium level during acute ischaemic stroke, being inversely associated with and predicting increased tHcy levels. While other studies suggested that selenium (through its role in selenoenzymes, thyroid hormones, and interactions with homocysteine and endothelial function) appears to be a major mediator in several pathways potentially contributing to chronic heart failure development [41]. The uterus showed hyperplasia in endometrium (Plate 7).

Effects of combination of NAC and Selenium on methionine treated rats

Both TBARS and GSH levels were restored to normal range values (control

values) with means (0.72 ± 0.17) and (25.33 ± 0.88) respectively. There is no demonstrated studies on the combined effects of NAC and selenium on methionine treated animals or their effects against hyperhomocysteinemia. The antioxidant status was improved in our study by combined treatment rather than their healing effect in the reproductive organs. The sections of ovary showed ovarian follicles at different stages of development, which indicate a clear reduction of methionine histotoxicity (Plate 8). The uterus also was similar to control rats as uterine glands (U), endometrium (E) and myometrium (M) were clearly appeared in the section (Plate 9). A significant synergistic action was observed in NAC and selenium combination for reducing the oxidative action of methionine.

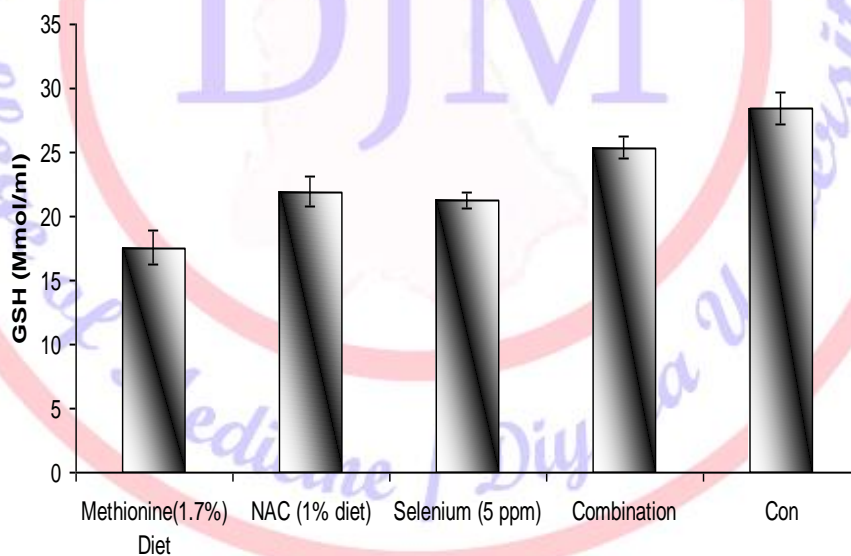


Figure (1): Effect of NAC, Selenium and their combination on serum in GSH methionine treated male rats.

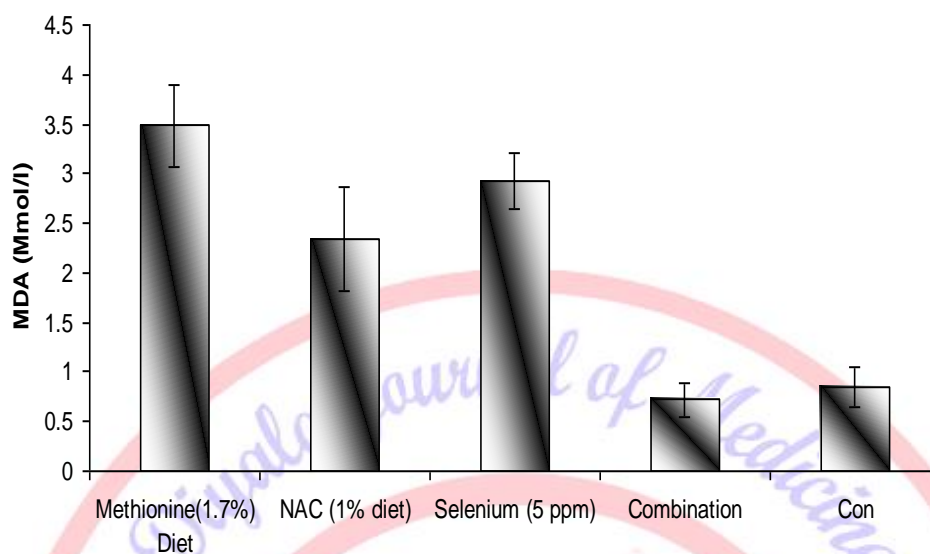


Figure (2): Effect of NAC, Selenium and their combination on serum TBARS in methionine treated male rats.

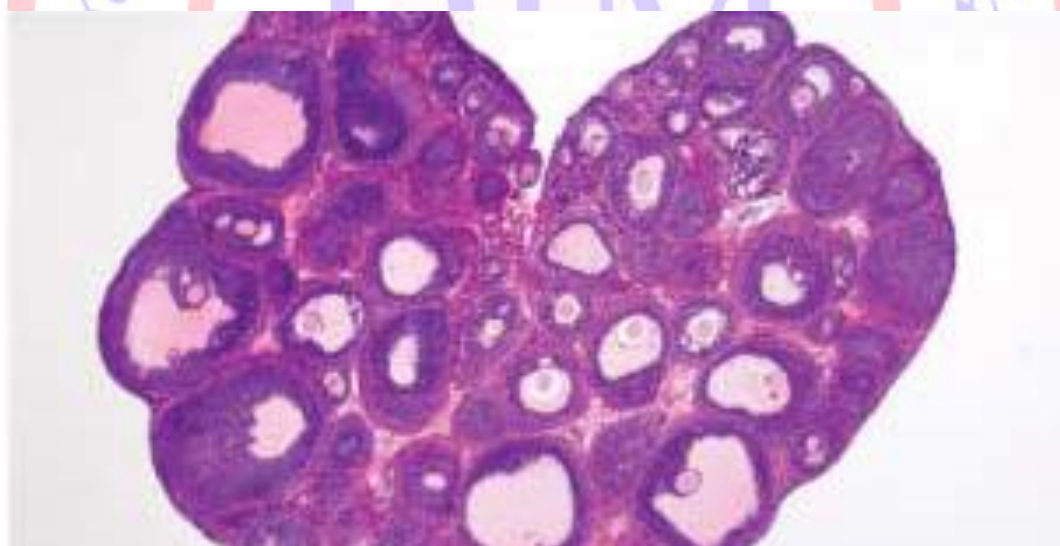


Plate (1): Control rat ovary, presence of ovarian follicles, at different stage of developments (H&E 68X).

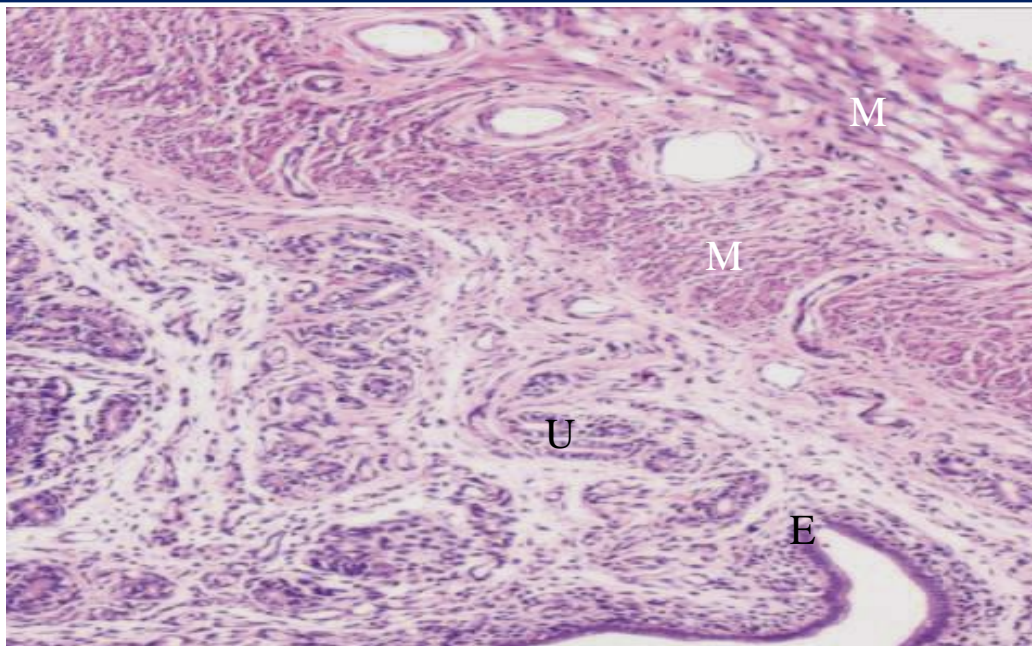


Plate (2): Control rat uterus. Endometrium (E) contains number of uterine gland (U), myometrium (M) longitudinal and crossing muscles (M). (H&E 100 X).

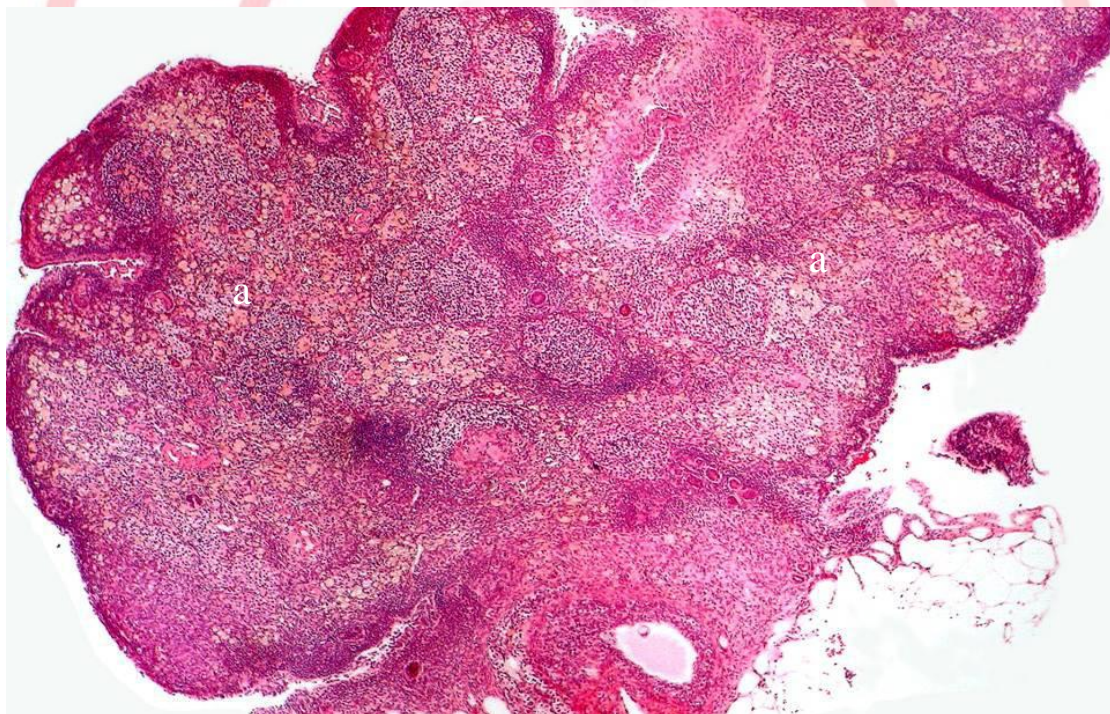


Plate (3): Cross section of rats ovary treated with methionin showed atrophy and ovarian follicles, undefined development stages, infiltration of inflammatory cells (a) (H&E 90 X).

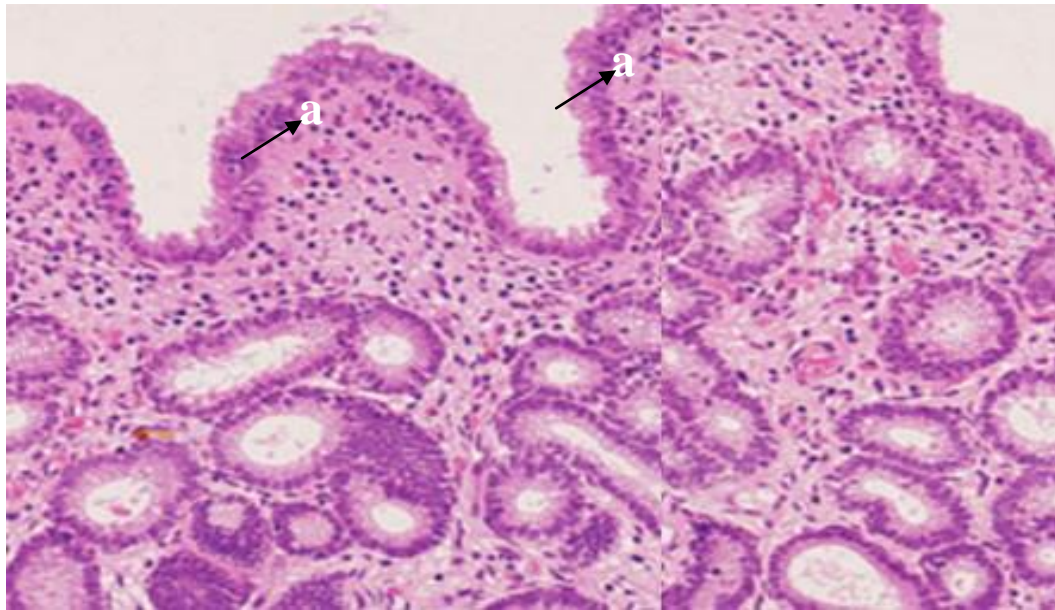


Plate (4): Cross section of uterine rats treated with methionin showed, infiltration of inflammatory cells (a) (H&E 145 X).

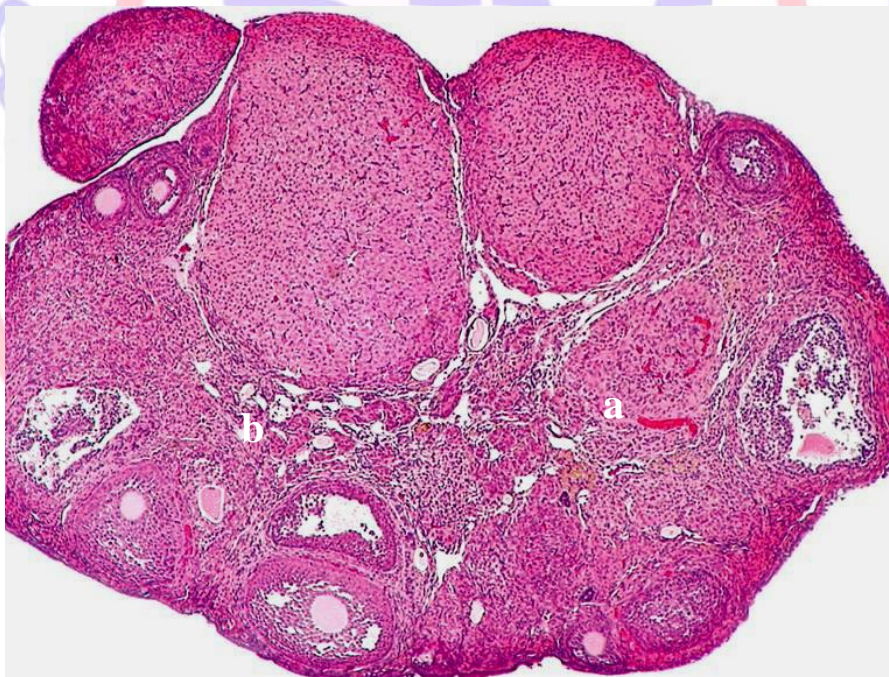

Plate (5): Cross sections of rats ovary treated with NAC showed congestion of blood vessels (a) and Some ovarian follicles were not developed (b) (H&E 68 X).

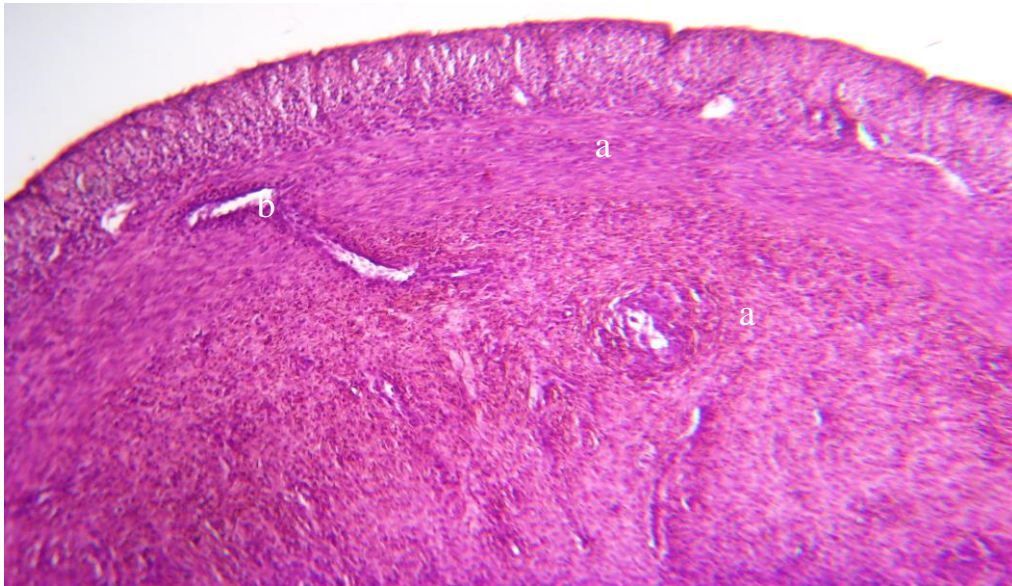

Plate (6): Cross section of uterian rat treated with NAC showed thickening myometrium (a) and atrophy of uterin gland (c). (H&E 68 X).

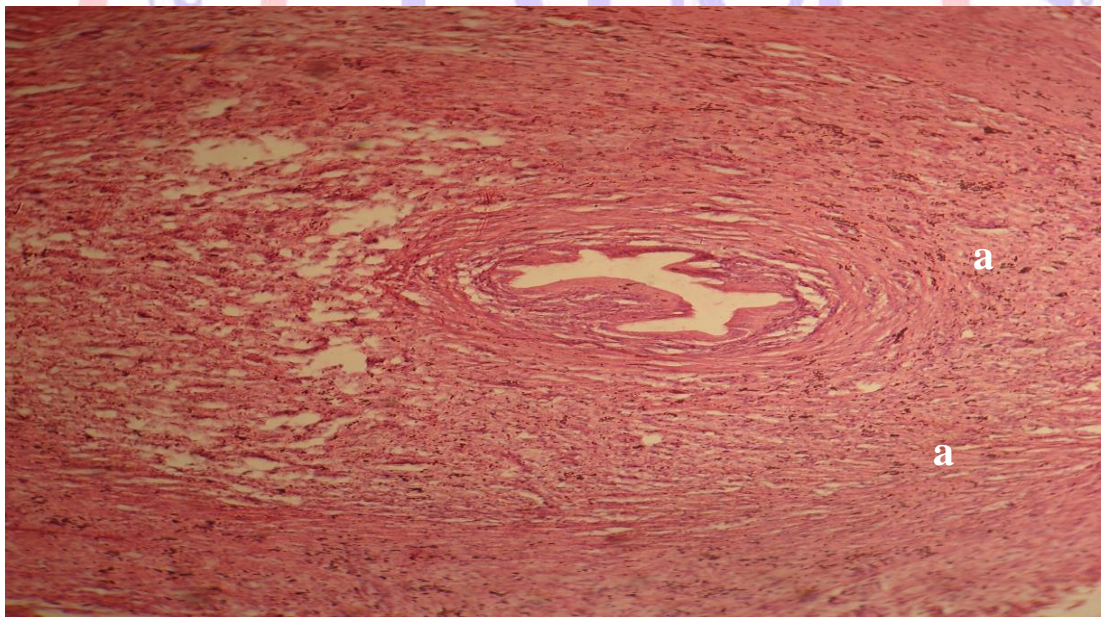


Plate (7): Cross section uterine rat treated with selenium hyperplasia in endometrium (a) (H&E 145 X).

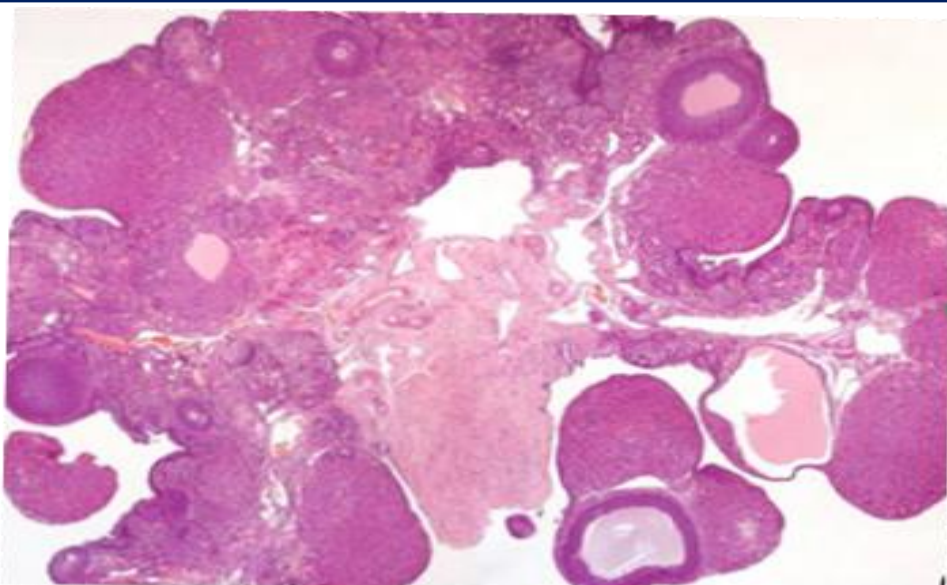


Plate (8): Cross section of ovarian rat treated with combination of NAC and selenium showed ovarian follicles at different stage of development (H&E 68X).

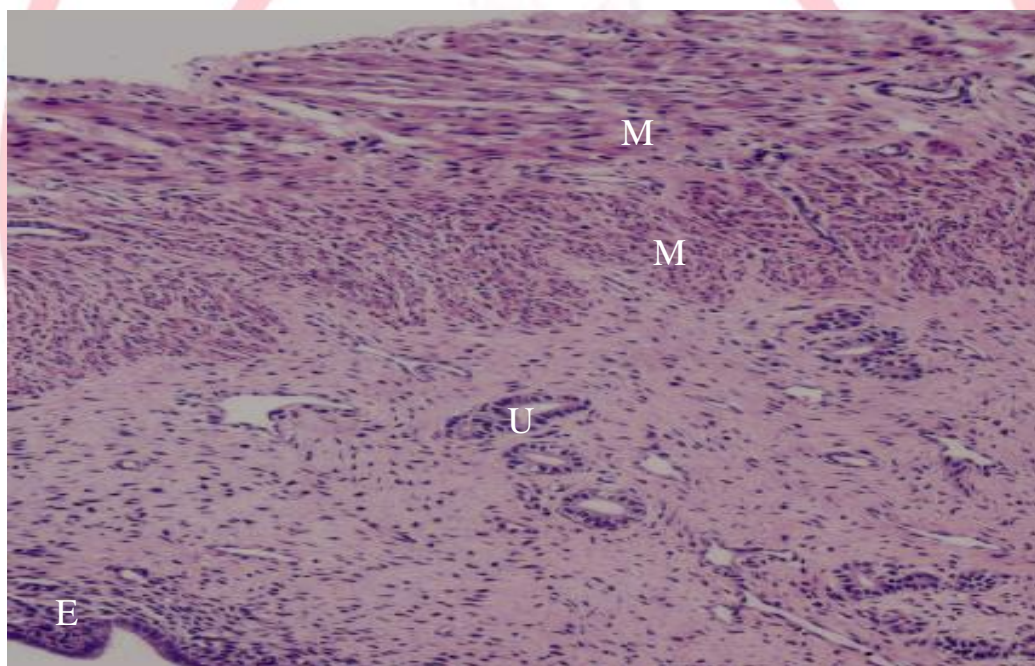


Plate (9): Cross section of ovarian rat treated with combination of NAC and selenium showed uterine glands (U), endometrium (E) and myometrium (M) similar to control uterus. (H&E 100X).

Referenes

- [1] Finkelstein, JD. (1998). The metabolism of homocysteine: Pathways and regulation. *Eur J Pediatr.* 157: 40-4.
- [2] Selhub, J., Jacques, P. F., Wilson, P.W.F., Rush, D. & Rosenberg, I. H. (1993) Vitamin status and intake as primary

determinants of homocysteinemia in an elderly population. *J. Am. Med. Assoc.* 270:2693-2698.

- [3] Welch, G. N. & Loscalzo, J. (1998) Homocysteine and atherothrombosis. *N. Engl. J. Med.* 338:1042-1050.

- [4] Nygard, O., Nordrehaug, J. E., Refsum, H., Ueland, P. M., Farstad, M. & Vollset, S. E. (1997) Plasma homocysteine levels and mortality in patients with coronary artery disease. *N. Engl. J. Med.* 337:230-236.
- [5] Weiss, N., Heydrick, S., Zhang, Y. Y., Bierl, C., Cap, A. & Loscalzo, J. (2002) Cellular redox state and endothelial dysfunction in mildly hyperhomocysteinemic cystathionine beta-synthase-deficient mice. *Arterioscler. Thromb. Vasc. Biol.* 22:34-41.
- [6] Matthias, D., Becker, C. H., Riezler, R. & Kindling, P. H. (1996) Homocysteine induced arteriosclerosis-like alterations of the aorta in normotensive and hypertensive rats following application of high doses of methionine. *Atherosclerosis* 122:201-216.
- [7] Tsai, J. C., Perrella, M. A., Yoshizumi, M., Hsieh, C. M., Haber, E., Schlegel, R. & Lee, M. E. (1994) Promotion of vascular smooth muscle cell growth by homocysteine: a link to atherosclerosis. *Proc. Natl. Acad. Sci. U.S.A.* 91:6369-6373.
- [8] Durand, P., Lussier, C. S. & Blache, D. (1997) Acute methionine load-induced HHcy enhances platelet aggregation, thromboxane biosynthesis, and macrophage-derived tissue factor activity in rats. *FASEB J.* 11:1157-1168.
- [9] Song Y, Cho M, Cho C, Rosenfeld M.E. (2009). Methionine-induced hyperhomocysteinemia modulates lipoprotein profile and oxidative stress but not progression of atherosclerosis in aged apolipoprotein E knockout mice. *J Med Food.* 12(1):137-44.
- [10] Refsum, H., Ueland, P. M., Nygard, O., and Vollset, S. E., (1998). Homocysteine and cardiovascular disease. *Annu. Rev. Med.*, 49:31-62.
- [11] Selhub, J., Jacques, P. F., Wilson, P. W., Rush, D. & Rosenberg, I. H. (1993) Vitamin status and intake as primary determinants of homocysteinemia in an elderly population. *J. Am. Med. Assoc.* 270: 2693-2698.
- [12] Fukada, S., Morita, T., and Sugiyama, K. (2008). Effects of Various Amino Acids on Methionine-Induced Hyperhomocysteinemia in Rats. *Biosci. Biotechnol. Biochem.*, 72 (7):1940-1943.
- [13] Verhoef, P., Steenge, G. R., Boelsma, E., van Viet, T., Olthof, M. R., and Katan, M. B. (2004). Dietary serine and cystine attenuate the homocysteine-raising effect of dietary methionine: a randomized crossover trial in humans. *Am. J. Clin. Nutr.*, 80:674-679.
- [14] Yilmaz H, Sahin S, Sayar N, Tangurek B, Yilmaz M, Nurkalem Z, Onturk E, Cakmak N, and Bolca O. (2007). Effects of folic acid and N-acetylcysteine on plasma homocysteine levels and endothelial function in patients with coronary artery disease. *Acta Cardiol.*;62(6):579-85.
- [15] Bunk, M. J. and Combs, G. F., Jr. (1981). Evidence for an impairment in the conversion of methionine to cysteine in selenium-deficient chick. *Proc. Soc. Exp. Biol. Med.* 167: 87-93.
- [16] Davis, C. D., Uthus, E. O. and Finley, J. W. (2000) Dietary selenium and arsenic affect DNA methylation in vitro in Caco-2 cells and in vivo in rat liver and colon. *J. Nutr.* 130: 2903-2909.
- [17] Davis, C. D. and Uthus, E. O. (2002) Dietary selenium and azadeoxycytidine treatment affect dimethylhydrazine-induced aberrant crypt formation in rat colon and DNA methylation in HT-29 cells. *J. Nutr.* 132: 292-297.
- [18] Coskun, O.; Ocakci, A.; Bayraktaroglu, T.; Kanter, M. (2004). Exercise training prevents & protects streptozotocin-induced oxidative stress & beta-cell damage in rat pancreas. *Tohoku. J. Exp. Med.* 203:145-54.
- [19] Karmin, O. Sun-Young, H. Yaw, L. Kathy, K. W. (2010). Folic acid supplementation inhibits NADPH oxidase-mediated superoxide anion production in the

- kidney. *Am J Physiol. Renal Physiol.* 300: 189-198.
- [20] Soudani N, Ben Amara I, Troudi A, Hakim A, Bouaziz H, Ayadi Makni F, Zeghal KM, Zeghal N. (2011). Oxidative damage induced by chromium (VI) in rat erythrocytes: protective effect of selenium. *J Physiol Biochem.* 67(4):577-88.
- [21] Kitamura Y, Nishikawa A, Nakamura H, Furukawa F, Imazawa T, Umemura T, Uchida K, Hirose M.(2005). Effects of N-acetylcysteine, quercetin, and phytic acid on spontaneous hepatic and renal lesions in LEC rats. *Toxicol Pathol.* 33(5):584-92.
- [22] Haen, P.J., (1995). Principles of Haematology.1st edition. Wm. C. Brown Publishers.
- [23] Al-Zamely, O.Y.; Al- Nimer, M. S. and Al-Muslih, R. K., (2001). Detection the level of peroxynitrite and related antioxidant status in the serum of patients with acute myocardial infraction. *Nation. J. Chem.* 4: 625-37.
- [24] Muslih, R.D.; Al-Nimer, O.M. and Al-Zamely, M.A. (2002): The level of Malondialdehyde after activation with (H₂O₂ and CuSO₄) and inhibited by Desferoxamine and Molsidomine in the serum of patients with acute myocardial infection. *Nat. J. Chem.* 5:148-9.
- [25] Bancroft, J .D.; Steven, A. and Dawson, I. (1977). Theory and Practice of Histological Techniques. Edinburgh, London, New York. Churchill-Livinstone.
- [26] Blalock, J. and Hubert M. (1979). Social Statistics. New York: McGraw Hill.
- [27] Nelen, W.L.(2001). Hyperhomocysteinemia and human reproduction. *Clin. Chem. Lab. Med.* 39:758-763.
- [28] Guzman, M., Navarro, M., Carnicer, R., Sarria, A., Acin, S., Arnal, C., Muneisa, P., Surra, J., Mainar, J., Maeda, N. and Osada, J. (2006). Cystationine beta- synthase is essential for female reproduction function.hum. *Mol. Gen.* 15(21):3168-3176.
- [29] Poddar, R., Sivasubramanian, N., DiBello, P., Robinson, K. & Jacobsen, D. W. (2001) Homocysteine induces expression and secretion of monocyte chemoattractant protein-1 and interleukin-8 in human aortic endothelial cells: implications for vascular disease. *Circulation* 103:2717-2723.
- [30] Wang, G., Siow, Y. L. & O, K. (2001) Homocysteine induces monocyte chemoattractant protein-1 expression by activating NF-kB in THP-1 macrophages. *Am. J. Physiol. Heart. Circ. Physiol.* 280: 2840-2847.
- [31] Xu, D., Neville, R. & Finkel, T. (2000) Homocysteine accelerates endothelial cell senescence. *FEBS Lett.* 470:20-24.
- [32] Zhang, R., Ma, J., Xia, M., Zhu, H. and Ling, W.(2004). Mild Hyperhomocysteinemia Induced by Feeding Rats Diets Rich in Methionine or Deficient in Folate Promotes Early Atherosclerotic Inflammatory Processes.*J. Nutr.* 134:825-830.
- [33] Najib, S. and Sanchez-Margalet, V. (2001). Homocysteine thiolactone inhibits insulin signaling, and glutathione has a protective effect. *J Mol Endocrinol*, 27: 85-91.
- [34] Kamellia R. Dimitrova, Kerry W. DeGroot, Alfonso M. Pacquing, Johan P. Suyderhoud, Eugen A. Pirovic, Thomas J. Munro, Jacqueline A. Wieneke, Adam K. Myers, and Young D. Kim. (2002). Estradiol prevents homocysteine-induced endothelial injury in male rats. *Cardiovasc Res*, 53: 589 - 596.
- [35] Bülent, B., Cemil K., Rusen A., and Hakan S. (2009). Homocysteine concentrations in follicular fluid are associated with poor oocyte and embryo qualities in polycystic ovary syndrome patients undergoing assisted reproduction. *Hum. Reprod.*, 24: 2293 - 2302.

[36] Durand, P., Lussier-Cacan, S. and Blache, D. (1997). Acute methionine load-induced hyperhomocysteinemia enhances platelet aggregation, thromboxane biosynthesis, and macrophage-derived tissue factor activity in rats FASEB J, 11: 1157 - 1168.

[37] Jin, L., Abou-Mohamed, G., Caldwell, B. and Caldwell, W. (2001). Endothelial cell dysfunction in a model of oxidative stress. Med Sci Monit. ,7(4):585-91.

[38] Ventura, P., Panini, R., Pasini, M.C., Scarpetta, G. and Salvioli, G. (1999). N - Acetyl-cysteine reduces homocysteine plasma levels after single intravenous administration by increasing thiols urinary excretion. Pharmacol Res. 40(4):345-50.

[39] Zinellu, A., Sotgia, S., Scanu, B., Usai, M.F., Fois, A.G., Spada, V., Deledda, A., Deiana, L., Pirina, P. and Carru, C. (2009). Simultaneous detection of N-acetyl-L-cysteine and physiological low molecular mass thiols in plasma by capillary electrophoresis. Amino Acids. 37(2):395-400.

[40] Angelova, E.A., Atanassova, P.A., Chalakova, N.T. and Dimitrov, B.D.(2008). Associations between serum selenium and total plasma homocysteine during the acute phase of ischaemic stroke. Eur Neurol. 60(6):298-303.

[41] de Lorgeril, M. and Salen, P. (2006). Selenium and antioxidant defenses as major mediators in the development of chronic heart failure. Heart Fail Rev. 11(1):13-7.