

STUDY THE PATHOGENESIS AND PATHOLOGICAL CHANGE IN LIVER AND LUNG OF CATTLE AND SHEEP WHICH INFESTED WITH HYDATED CYST LARVAL STAGE IN DIYALA PROVINCE

Ahmed Jasem Albayaty^{1,4}

Shatha Qassim Jwad²

Dalia A. Abdullshahid³

Hiba Yaseen Abbas¹

¹ College of Vet. Med., University of Diyala, Iraq.

^{2,3} College of Dentistry and College of Vet. Medicine, respectively, University of Baghdad, Iraq.

⁴ Corresponding author: dr.ahmed201499@gmail.com

ABSTRACT

The study was conducted in Diyala governorate to show the prevalence of hydatid cyst among slaughtered animals during the period from 11/10/2016 to 30/4/2017. The slaughtered animals were local breeds, of both sexes (males and females), different ages and from different regions in Diyala Province. The hepatic cysts were severely examined with the naked eye and the body. The study was conducted on 10 heads of cattle and 10 head of sheep. The study was compared with hepatitis in sheep and cattle lungs and found in sheep and cattle liver. The total pathological changes of the liver showed varied agree of necrosis represented in enlargement, discoloration to the dark and red regions surrounding the cysts hydeidate as a reaction to inflammation. Cysts protruding mostly from the surface of the organ and sometimes embedded. A white wall covered cysts has been observed. Histological changes of the liver and lung are represented by infiltration of inflammatory cells such as neutrophils, monocytes and glands. Liver and lung cells appeared separate from each other and there was a vacancy in liver tissue.

Key words: cattle, sheep, hydatid cyst.

INTRODUCTIN

Echinococcosis (hydatid disease) is one of the most important public health and economic problems in different countries including Iraq. Hydatid disease is a zoonosis caused by the tapeworm of *Echinococcus spp.* These species include *E. granulose*, *E. multilocularis*, *E. vogeli* or *E. oligarthrus* (Lewis, *et al.* 1975). Which live as a small intestinal tapeworm of dogs, and occasionally other carnivores (Dent and Kelly, 1976) (definitive host). Their larval form causes hydatidosis in domestic animals and man (intermediate host) (Baldock, *et al.*, 1985) Shedding of gravid proglottids or eggs in the feces occurs within 4–6 weeks after infection of the definitive host. Ingestion of eggs by intermediate host animals (sheep, cattle, goats, horses, camels) or human results in the release

of an oncosphere into the gastrointestinal tract which then migrates with blood stream to primary target organs such as liver and lungs and less frequently to other organs (Dai *et al.*, 2004). Usually the fully mature metacestode (i.e. hydatid cyst) develops within several months or years. The spread of disease mostly in field when livestock are raised with dog such as in endemic area (Duncan *et al.*, 1955) include Australia, Latin America, Europe, Africa and the Middle East (Schaefer and Khan, 1991). Liver is the most common site of cystic development, in over 90% of liver cysts; the oncosphere is trapped in the central veins of the hepatic lobules and the resultant cyst may be deep or superficial and it causes compression of the liver cells which can lead to biliary stasis and cholangitis (Kebede *et al.*, 2009) The cyst may present as a liver abscess and large cyst can produce localized or diffuse hepatomegaly (Moro *et al.*, 2000). The local pathological effects depend on the site of the hydatid cyst; ruptured liver cyst through the diaphragm can produce a pleural effusion or bronchobiliary fistula (Gerazounis *et al.*, 2002). The parasite destroys the liver parenchyma, bile ducts and blood vessels resulting in, symptoms of biliary obstruction, portal hypertension and necrosis of the central, portion of the cyst with abscess formation. Growth of the germinal membrane into blood vessels produces metastasis to almost any organ, but they are more commonly found in the lungs and brain (Gutierrez, 1990).

The first described of disease which is synonym for the infection with hydatid cyst was in Bible and also referred to by the Babylonians (Ritter, *et al.*, 1987), the disease has been described by Hippocrates (460- 379 BC) that the liver is filled with water and cause serious illness and when the outburst may lead to death (Lewis *et al.*, 1975) The Greeks description of these worms and named it Lubricous lotus meaning broad worms, and these facts remain for many centuries (Dent and Kelly, 1976).

Adult *Echinococcus granulose* length of 2-8 mm reside in intestine of dog and other canine infection with hydatid cyst occurs through fecal-oral transmission contaminated food and water with infected stage (egg) and direct contact with infected dog consider to be source of infection (Schaefer and Khan, 1991). Egg hatching and out of hexacanth embryo in small intestine of intermediate host which penetrated the intestinal wall and reach the blood move to liver, lung and various places in body form the hydatid cyst rings between 1-15 cm (Amman and Eckert, 1996).

Echinococcosis is the most important zoonotic diseases that infect animals, which mentions that it is zoonotic diseases transmitted to human from dogs and other final hosts, where most of the world suffer from the spread of this disease, especially developing countries (Kebede *et al.*, 2009). This disease in Iraq in terms of epidemiological consider hyper endemic to the presence of large numbers of stray dogs infected with adult *Echinococcus granulose* which discard eggs containing hexacanth embryo, which in turn infect intermediate hosts (Moro *et al.*, 2000) also the disease in Iraq called cancer of Iraq (Gerazounis *et al.*, 2002).

Due to the spread of this disease in productive animals broadly, it is classified among the diseases that cause significant economic losses in livestock as a result of the destruction of the affected organs with hydatid cysts (Serefettin *et al.*, 2003).

Methods of transmission:

1. By hand to mouth through the seam with the tools contaminated with the feces of infected dogs.
2. Eat foods such as fresh vegetables or water contaminated with tapeworm eggs from dog feces.
3. Directly from infected dogs to humans by touching them or playing with them. Dogs usually lick an anal area where his mouth is contaminated with eggs during licking and spread eggs on his hair and then move to the human when it touches infected dogs.
4. Feeding herbivores on pasture or feed contaminated with tapeworm eggs from dog feces.

METHOD AND MATERIAL

It was taken bags Ad rah samples from the livers of sheep (5 samples) and (5 samples) of bags liver in infected cows from the shops butchers in Diyala province during the month in December and January for the year 2016-2017 and measure the dimensions of the bags tissue of these livers spaces certain to read the effect of patients these bags on liver tissue found that the bleeding pontifical and pale in the livers of infected sheep, in addition to calcification in the livers of cows most important pests macroscopic seen either tissue lesions were observed fibrous layer and thick layer of necrosis and infiltration acidophilus cell mass and wide calcification all parts of the affected area in the livers of the Infected tar appeared moral influence in the amount of fluid Aladra and the thickness of the fibrous layer and layer thickness necrosis.

The study also examined of Histopathological changes caused by *Echinococcus grnulosus* in the bronchial tubes of the sheep lungs and the naturally programmed cows. Histopathological changes have been histologically identified by sequential waxy sections, with severe pathogenic lesions in the lung cavity and causing hypotension in the lung, vision of the lung, enlargement of the bronchioles, and bronchitis, where lung bags cause lung failure, changes in the walls of blood vessels, hemorrhage and vision.

RESULTS AND DISCUSSION

The samples were evaluated grossly and histology

Grossly:

Sheep:

Sterile cysts: petechial hemorrhage and infiltrations inflammatory cells around cysts.

Fertile cysts: blood patches, infiltrations of inflammatory cells around cysts and paleness of most areas of liver.

Cows:

Sterile cysts: calcifications, blood patches and infiltrations of inflammatory cells around cysts and pale on margins of liver. Length, width and amount of fluid in sheep for sterile hydatid cysts were 5.25 centimeters (cm), 2.50 cm and 16.33 milliliters (ml) respectively while for fertile hydatid cysts were 5.50 cm, 3.50 cm and 27.80 ml respectively. In cows for sterile hydatid cysts were 5.50 cm, 2.50 cm and 8.58 ml respectively (Tables 1 and 2). The significant effect exist at $p \leq 0.05$ of amount of fluid of hydatid cysts (SAS, 2000).

Histology

Sheep:

Sterile cysts: Thickened fibrous layer and sever necrosis (nuclei of hepatocytes appear in different stages of necrosis, some nuclei appear pyknotic or Karyorrhesis while other appear karyolysis) with infiltrations of eosinophil (eosinophilia). After these layers, the normal tissue appears with normal hepatocytes and Sino sides without infiltrations of inflammatory cells (Fig. 2 and 3).

Fertile cysts: Thickened fibrous layer and sever necrosis with eosinophilia and severe scattered of inflammatory cells with fibrous tissue. After these layers, the normal tissue appears with foci of inflammatory cells (Fig. 7 and 10).

Cows:

Sterile cysts: Thickened fibrous layer and sever necrosis with *eosinophilia and extensive calcification along hepatic tissue. The normal tissue* (Fig. 1 and 4)

appears with severe scattered of inflammatory cells and fibrous tissue thickness of fibrous layer of sterile and fertile hydatid cysts in sheep and sterile cysts in cows were 47.50 micrometer, 48.42 micrometer and 93.94 micrometer respectively, thickness of necrotic layer in sheep of sterile and fertile hydatid cysts and sterile cysts in cows were 61.15 micrometer, 73.17 micrometer and 45.50 micrometer respectively. The significant effect exist at $p \leq 0.05$ (Table 2) (fig. 4 and 5).

Table 1. Length of sterile and fertile hydatid cysts in sheep and cows

	Sheep		Cow	Significant level
	Sterile cysts	Fertile cysts	Sterile cysts	
Length of cysts (cm)	5.25	5.50	5.50	N.S
Width of cysts (cm)	2.50	3.50	2.50	N.S

Table 2. amount of fluid of sterile and fertile hydatid cysts in sheep and cows

	Sheep		Cow	Significant level
	Sterile cysts	Fertile cysts	Sterile cysts	
Amount of fluid of cysts (cm ³)	16.33	27.80	8.58	0.05

Grossly:

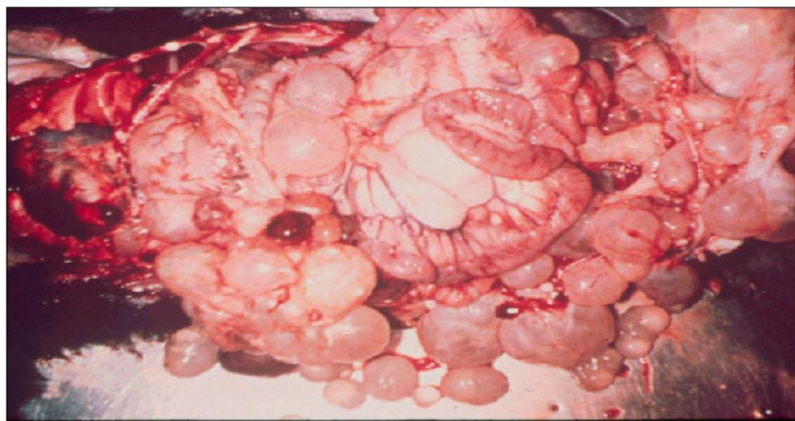

Fig. 1. Liver and lung of cattle infected with hydatid cyst

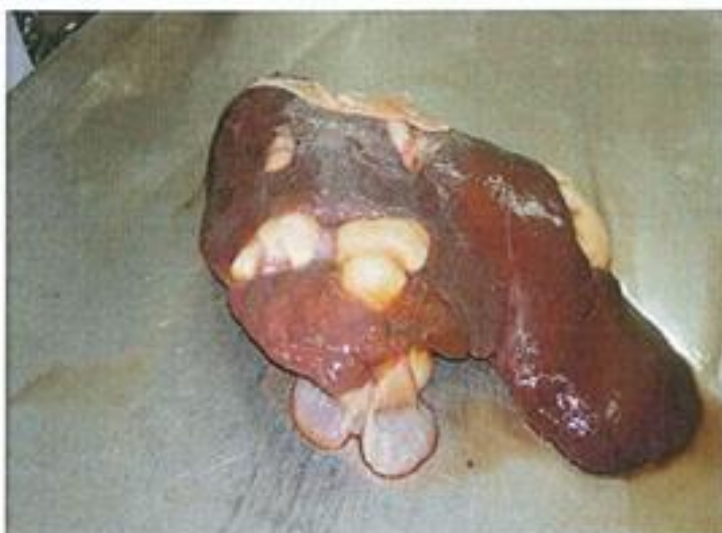

Fig. 2. Liver of sheep infected with hydatid cyst

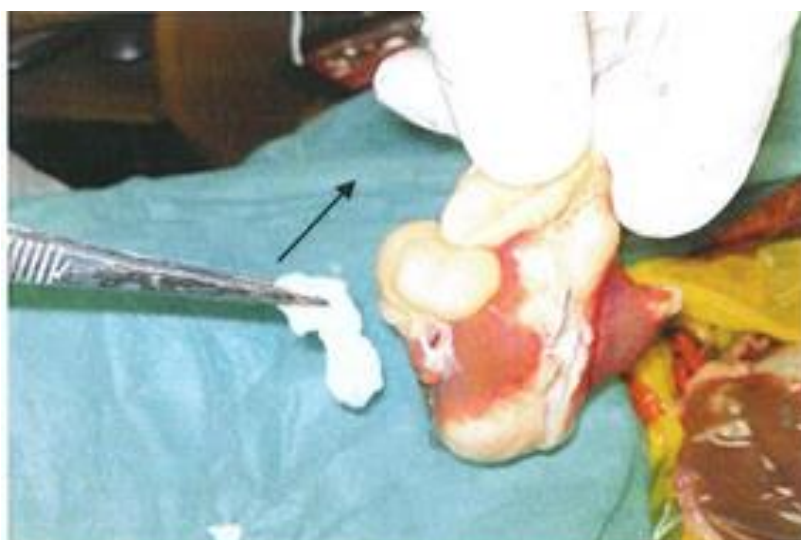

Fig. 3. Liver of sheep infected with hydatid cyst

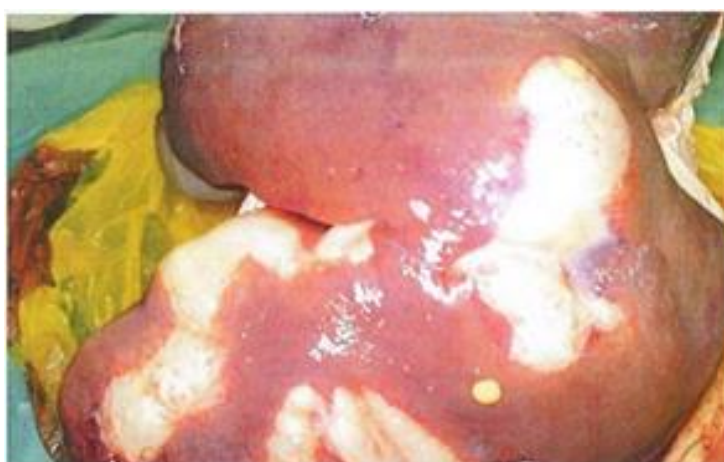

Fig. 4. Liver of cattle infected with hydatid cyst

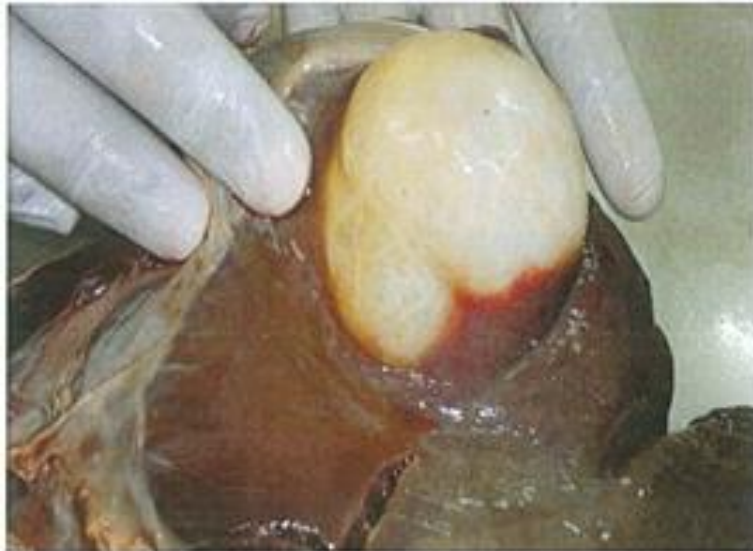

Fig. 5. Liver of cattle infected with hydatid cyst

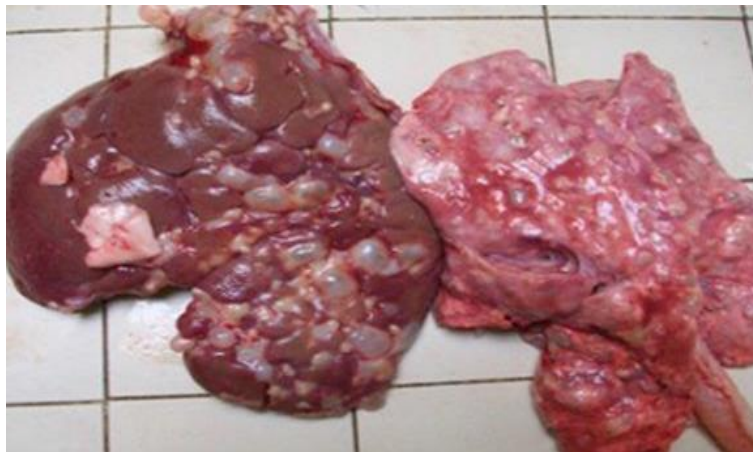

Fig. 6. Liver and lung of sheep infected in hydatid cyst

Histopathological:-

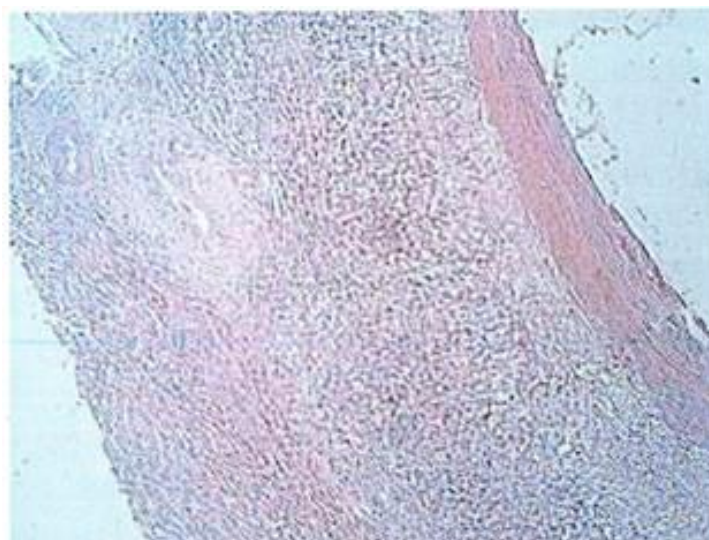


Fig. 7. Thickened fibrous Layer and sever necrosis of sterile cysts in lung of sheep

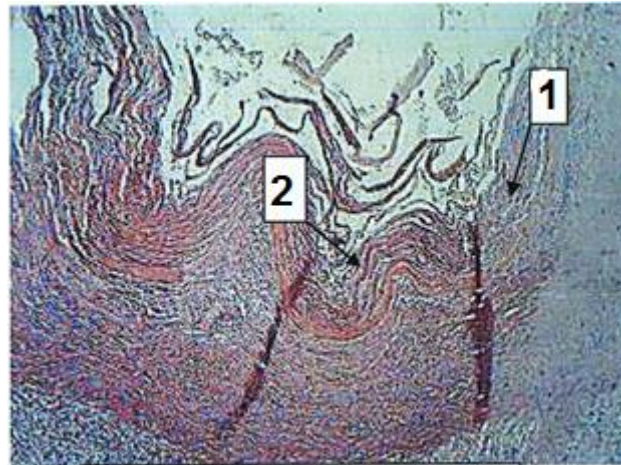


Fig. 8. Thickened fibrous Layer (1) and sever necrosis (2) of sterile cysts in lung of cattle

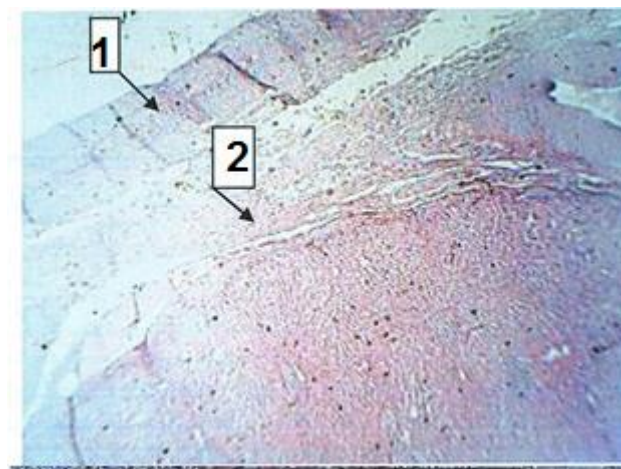

Fig. 9. Fibrous Layer (1) and sever necrosis with eosinophilia (2) of fertile in liver of cattle

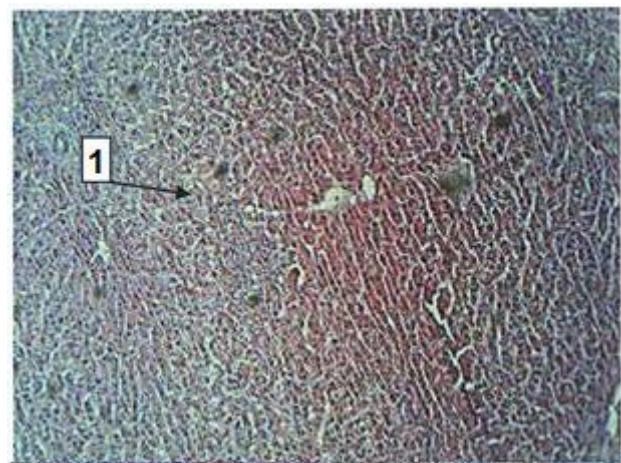


Fig. 10. Fibrous Layer with sever infiltration of inflammatory cells with fibrous tissue (1) of sterile cysts in liver of sheep

The present study revealed that the presence of hydatid cysts in the liver of sheep and cows resulted in different histological lesions represented in inflammatory reaction, fibrosis and necrosis in the area near to the cysts. Such of

these effects were mostly documented in different animals infected with different species of *Echinococcus*. In goat and sheep (Smyth *et al.*, 1980) the infection showed evidence of marked host cellular reaction consisting of infiltration of the adventitial layer with neutrophils, eosinophil's, and plasma cells. In addition to this inflammatory infiltrate, the new space between the liver tissue and cyst wall contained disorganized fibroblasts and mesenchymal cells. In the most necrotic areas, the laminate layer could not be collected together with adherent liver tissue and the adventitial layer appeared completely degenerated and it was replaced by acute inflammatory cells. Also, suggested that the liver cell necrosis may be either due to progressive action of intracellular enzymes of the injured cells or to a metabolic disturbance and inhibition of synthesis needed of DNA and hence protein synthesis. There is significant effect of amount of hydatid cyst which is higher in fertile cyst that contain alive and proliferated protoscolex which based on hydatid fluid components in nutritional requirements. The thickness of fibrous and necrotic layer is significantly affect between sheep and cows due to different of defense mechanism and cellular effects with difference of animal species.

In conclusion, echinococcosis is still an important health problem in Iraq that needs further study. The people traveling to endemic areas should be educated not to contact with wild animals. There is a need for a suitable eradication program, so that untreated dogs as well as foxes, which play an important role in the contagiousness of the disease in rural areas, can be eradicated as an infectious agent (Smyth *et al.*, 1974).

REFERENCE

- Amman, R. W. and J. Eckert. 1996. Cestodes: *Echinococcus*. *Gastroenterol. Clin. North Am.*, 25: 655-689.
- Baldock, F. C., R. A. Thompson and L. M. Kumaratilake. 1985. Strain identification of *E. granulosus* in determining origin of infection in a case of human hydatid disease in Australia. *Trans. Roy. Soc. Trop. Med. Hyg.*, 79: 175-180.
- Blanton, R., M. Ernest, T. Wachira, K. Magambo, E. Zeyhle and P. Schantz. 1998. Oxfendazole Treatment for Cystic Hydatid Disease in Naturally Infected Animals. *Am. Soc. Microbiol.*, 42(3): 601-605.
- Dai, W., A. Waldvogel, M. Siles-Lucas and B. Gottstein. 2004. *Echinococcus multilocularis* proliferation in mice and respective parasite 14-3-gene expression is mainly controlled by an $\alpha \beta$ ++ CD4 T-cell- mediated immune response. *Immunology*, 112: 481-488.

- Dent, C. R. and J. D. Kelly. 1976. Cestodes parasites of dog in central table land of New South Wales. *Aust. Vet. J.*, 52: 386-388.
- Duncan, D. B. 1955. Multiple range and multiple F tests. *Biometrics*, 11: 1-42.
- Gerazounis, M., K. Athanassiadi, E. Metaxas, M. Athanassiou and N. Kalantzi. 2002. Bronchobiliary fistulae due to echinococcosis. *Eur. J. Cardiothorac. Surg.*, 22: 306-308.
- Gutierrez, Y. 1990. Diagnostic Pathology of Parasitic Infections with Clinical Correlations. Philadelphia: Lea and Febiger., 460-480.
- Kebede, N., A. Mitiku and G. Tilabun. 2009. Hydatidosis of slaughtered animals in Bahir Dar abattoir, northwestern Ethiopia. *Trop. Anim. Health Prod.*, 41(1): 43-50.
- Lewis, J. W., N. Koss and M. D. Kerstein. 1975. A review of echinococcal disease. *Ann. Sug.*, 181: 390-396.
- Moro, P. L., A. E. Gonzalez and R. H. Gilman. 2000. Cystic hydatid diseases. In: Hunter's Tropical Medicine and Emerging Infectious Disease, 8th ed. (Stickland G. T.) W. E. Saunders Co. USA: 866-871.
- Ritter, E. J. 1987. Altered Biosynthesis. In: Handbook of Teratology. Vol.2 Plenum Press, New York.
- SAS. 2001. SAs users guide. Statistics version 6.12. SAS institute, Inc, Cary, NC.
- Schaefer, J. W. and M. Y. Khan. 1991. Echinococcosis (hydatid disease): lessons from experience with 59 patients. *Rev. Infect. Dis.*, 13: 243-247.
- Serefettin, M., G. Merih, C. Tulay and H. Astarcioglu. 2003. The Pathology of Echinococcosis and the Current Echinococcosis Problem in Western Turkey (A Report of Pathologic Features in 80 Cases). *Turk. J. Med. Sci.*, 33: 369-374.
- Smyth, J. and N. J. Baret. 1980. Procedure for testing viability of human hydefid cyst folling surgical, especially after chemotherapy .*Trans Roy Soc Trop Med Hyg* 74: 5.
- Smyth, J. D. and Z. davies. 1974. accourance of physiolyicd strains of Echinococcus granulosus demonstrated by invitro culture of protoscolices from sheep and horse hydetid cyst. *Inf. J. parasitol.* 4: 443-445.

دراسة التغيرات المرضية الناجمة عن الإصابة بطور اليرقة لطفيلي الأكياس المائية في الأبقار والأغنام في محافظة ديالى

هبة ياسين عباس⁴داليا عبد الشهيد³شذى قاسم جواد²أحمد جاسم البياتي¹^{4,1} كلية الطب البيطري، جامعة ديالى، العراق.^{3,2} كلية طب الأسنان وكلية الطب البيطري على التوالي، جامعة بغداد، العراق.⁴ المسؤول عن النشر: dr.ahmed201499@gmail.com

المستخلص

اجريت الدراسة الحالية في محافظة ديالى لإظهار مدى انتشار الاكياس العدرية بين الحيوانات المذبوحة خلال الفترة من 2016/10/11 لغاية 2017/4/30، وكانت الحيوانات المذبوحة من سلالات محلية، من كلا الجنسين (ذكور وإناث) وأعمار مختلفة ومن مناطق مختلفة في محافظة ديالى. وفحصت الاكياس العدرية بالعين المجردة والجس وأجريت الدراسة على 10 من الأبقار و10 من الأغنام، وتم مقارنة الاكياس الموجودة في رئة الأبقار والأغنام وكذلك الموجودة في أكباد الأغنام والأبقار، وقد أظهرت التغيرات المرضية الإجمالية للكبد نتائج متنوعة من تنخر متمثلة في التوسيع، وتلون المنطقة المحيطة بالاكياس العدرية باللون الاحمر بسبب رد فعل الالتهابات. وتكون الاكياس العدرية في الغالب على سطح العضو المصاب، وقد لوحظت الاكياس العدرية مغطاة بجدار أبيض. والتغيرات النسيجية للكبد والرئة متمثلة تسلسل الالتهابات خلايا مثل العدلات، وحيدات والبلعميات. وظهرت خلايا الكبد والرئة منفصلة من بعضها البعض وكان هناك إخلاء في أنسجة الكبد.

الكلمات المفتاحية: ابقار، اغنام، اكياس عدرية.