

ROLE OF PLATELETS RICH PLASMA AND PLATELETS RICH FIBRIN MATRIX IN TREATMENT OF CHRONIC WOUNDS IN BUCKS

Falah Hassan Khalaf^{1,3}

Serwa Ibrahim Salih²

^{1,2} Dept. of Surgery and Obstetrics, College of Vet. Med., Univ. of Diyala and Baghdad respectively.

³Corresponding author: fhkhalf@gmail.com

ABSTRACT

The aims of this study was to evaluate the effects of platelet-rich plasma gel (PRP) and platelet-rich fibrin matrix (PRF) application on the induced open chronic wounds in bucks by clinical and biomechanical estimation.

Twenty – four adult bucks were used in this study. Skin and subcutaneous tissues were removed to make four square full-thickness skin wounds (4×4 cm) on the dorsal sides of the back of each animal (two wounds on each side), 10 cm apart after preparation of the area in routine surgical manner one for treatment group and second as control group, by daily scratched to interrupt healing process continuation to prolong inflammatory reaction to form chronic wound. This surgical procedure was continued for eight week to ensure the chronicity state of these wounds, then they were treated by PRP gel in first group (n=12), while PRF matrix was used in second group (n=12). PRP gel and PRF matrix were prepared from whole blood at time of treatment, with leave two wounds of each animal as control for treated type. Healing process was evaluated clinically by measuring wound size of both treated and control groups, and throughout experimental time and biomechanical assessment of healing wounds in 45 day post operation.

The healing process of treated wounds showed significant variation in wound's dimensions of both treated groups in comparison to their control group without significant in between them, while the biomechanical evaluation indicated increasing in tensile strength of both treated groups in comparison to control group.

The conclusions of this work is the continuous mechanical irritation of wounds site may lead to form chronicity state for the effected wounds and the application of PRP or PRF may improve healing process and increased wound tensile strength without any adverse effect, and biomechanical assessment of wound tensile strength of PRP and PRF groups within same consequences and provided a good indication of wound healing process.

Key words: chronic wound, platelet rich plasma, platelet rich fibrin matrix.

INTRODUCTION

A wound can be defined as damage or disruption of the normal anatomical structure and function (Robson *et al.*, 2001). Wounds can be classified as acute or chronic wounds. Chronic wounds are defined as wounds that fail to proceed through the normal phases of wound healing in an orderly and timely manner (Robson *et al.*, 2001; Situm and Kolić, 2012). Chronic wounds develop when there is a disruption in the normal healing process. Wounds that have failed to progress through a normal sequence of repair in 4 to 8 weeks are generally presumed to be chronic. (Izadi and Ganchi, 2005 ; Frykberg and Banks, 2015).

Platelets are cytoplasmic fragments of megakaryocytes, functioning to form the initial hemostatic plug to damaged vasculature and to maintain vascular integrity (Jones and Allison, 2007). The α granules of platelets contain numerous growth factors including platelet-derived growth factor (PDGF), transforming growth factor- β (TGF- β), vascular endothelial growth factor (VEGF), fibroblast growth factor (FGF), insulin-like growth factor (IGF), and epidermal growth factor (EGF). Bioactive factors such as serotonin, histamine, dopamine, calcium, and adenosine are also stored in the dense granules (Fufa *et al.*, 2008).

Platelet-rich plasma (PRP) is a portion of the plasma fraction that has a platelet concentration above baseline values (Pietrzak and Eppley, 2005). PRP works by secretion of growth factors following platelet activation, and released growth factors bind to the external surface of cell membranes in applied tissue. The release of growth factors at the site of injury in higher concentrations than those found in whole blood helps the healing of tissues because these factors contribute to several required processes, such as cell proliferation, chemotaxis, cell differentiation, and angiogenesis (Foster *et al.*, 2009). The effect of PRP on cutaneous wound healing was described in horses, dogs, goats and others animals species (Kim *et al.*, 2009 ; DeRossi *et al.*, 2009 ; Sardari *et al.*, 2011; Al-Bayati *et al.*, 2013).

Platelet rich fibrin (PRF) was developed by Choukroun *et al.*, (2001) for specific use in oral and maxillofacial surgery and represents a step forward in ease of production of the fibrin gel (Dohan *et al.*, 2006). The PRF clot is obtained by inducing a normal polymerization procedure during centrifugation without addition of anticoagulants. PRF provides appropriate surface for tissue regeneration and healing henceforward (Simonpieri *et al.*, 2012).

The objectives of this study were to evaluate using of platelet rich fibrin (PRF) and Platelet rich plasma (PRP) on the healing process of chronic wound by clinical and biomechanical estimation.

MATERIALS AND METHODS

Twenty – four adult apparently healthy local breed bucks were used, their body weights between 25-35 Kg and aged 2-3 years. They were examined physically and clinically. All animals were housed under similar management conditions and feeding. The animals were divided into two equal treated groups at time of treatment one for PRP and second for PRF treatment.

The blood samples were collected aseptically by aspiration technique into syringe (20 ml) containing 2 ml 3.8% sodium citrate as anticoagulant (Dorothy *et al.*, 1997), and divided into two tubes 10 ml of each one and centrifuged (Electric centrifuge, China) at 2800 rpm for 15 minutes. This procedure divides the blood into three basic parts: platelet poor plasma (PPP) at the top of the tube, platelet rich plasma (PRP) in the middle and red blood cells at the bottom. After the first centrifugation, the whole plasma fraction above the buffy coat was transferred to empty tube by aseptic technique. The buffy coat of each tube, contained mononuclear cells and platelets. The final solution obtained by mixing different buffy coats in a sterile 10 ml tube, was second centrifuged at 2800 rpm for 15 min for good separation of platelets in two layers. The platelet collected at the bottom of the tube, the PPP on top. The PPP was drawn off so that the PRP remained in the tube, the final PRP was obtained approximately 1ml, drawn up with an insulin syringe into a petri dish and the platelets were activated by adding 0.2 ml of 10% calcium chloride to form PRP gel which was used in the wounded area (Perazzi *et al* 2013 ; Shin *et al*, 2017) (Figure 1).

The procedure for PRF preparation included pooling of whole venous blood (10 ml) in each of the two sterile tubes (10 ml) without anticoagulant and the tubes were immediately placed in a centrifugal machine at 3000 rpm for 10 min, after which it settled into the following three layers: Upper straw-colored a cellular plasma, red-colored lower fraction containing red blood cells (RBCs), and the middle fraction containing the fibrin clot. The upper straw-colored layer was removed and middle fraction was collected which was PRF A fibrin clot is then formed in the middle between the red blood cells at bottom and a cellular plasma at the top. The middle part was platelets trapped massively in fibrin meshes. The fibrin clot then was withdrawn up with thumb forceps from tube and cutting off the red blood cell that adhered with it, the clot was squeezed between two sterile gauge pieces to obtain autologous fibrin membrane (Dohan and Choukroun, 2006 ; Raja and Naidu, 2008) (Figure 2).

Surgical Procedure

Food was withdrawn for 24 hrs and water restricted 12 hrs. before surgery. Under light sedation, by using xylazine hydrochloride (Xyla –MD, Germany) in a dose of 0.2 mg kg⁻¹ B.W. I.M and local anesthesia by using inverted L technique at wound borders with lidocaine hydrochloride. Under aseptic technique skin and subcutaneous tissues were removed to make four square full-thickness skin wounds (4×4 cm) on the dorsal sides of the back of each animal (two wounds on each side) 10 cm apart, one for treated group and second as control group (Figure 3). Under local anesthetic effect by using lidocaine hydrochloride spray 10% the wounds were daily scratched and eroded to remove newly formed cells to prevent new tissues formation in wound bed and transform it to chronic wound. This surgical procedure was repeated for eight weeks to ensure chronicity state ((Izadi and Ganchi, 2005), with weekly measurement of wounds dimensions. The animals were subdivided randomly into two equal groups (12 animal in each one) at treatment time, first group (PRP group) and second group (PRF group). The wounds after that were treated, using PRP and PRF which was prepared as previously described, directly at time of treatment. The wounds were treated twice with PRP and PRF in one week interval, as an initial and second treatment.

Statistical Analysis

Statistical Analysis System-SAS (2012) program was used. Least Significant Difference - LSD test was used for significant comparison between means in this study.

RESULTS

Clinical findings of the present study can be put in two categories as following:

Period of inducing wounds: this period started from time of inducing surgical wounds which took eight weeks with daily mechanical irritation to create a chronic state. Clinical follow-up in this period showed systemic reaction, characterized by anorexia, depression and lethargy in the first three days post operation, disappeared gradually within first 3 days to become within normal values. While local inflammatory reaction persisted and were graded from slight to moderate inflammatory swelling with bloody clots formation, inflammatory exudate without signs of infection in all animals during this period (Figure 4), except one case, which had scanty pus formation in one wound appeared in the first 3 days post operation, which was treated locally with

povidone iodine 10% for 5 days and systemic antibiotic (20 mg kg⁻¹ B.W. oxytetracycline).

In this study both platelets rich plasma gel and autologous platelets rich fibrin matrix were used in treatment of induced open chronic cutaneous wounds in bucks, after making sure that the wounds became chronic.

Period of treatment: A complete clinical examination was performed on all animals daily during the treatment periods, clinical findings showed no infection and all wounds continued on healing process without signs of complications in all animals, physiological parameters were in normal values (body temperature, appetite, heart and respiratory rate) during study period, and all wounds went on normal healing process, with superiority of treated wounds of both PRP and PRFM groups, in signs of scar formation and wound's dimensions in comparison with their control.

Wound healing was evaluated clinically in this study by measuring the wound dimensions as sign of wound contraction, comparison between the obtained results of treated wounds with control group and between two treated groups to evaluate healing process in all groups as the following:

First group (PRP group): Results of this group showed no significant variation ($P < 0.05$) in wounds dimensions in the first two weeks between their control (7.30 ± 0.33) and PRP group (6.55 ± 0.30), and in third week they became significant (3.33 ± 0.48) of treated in comparison with control group (4.84 ± 0.23), in which the significant value was existed till the end of the study (Table 1).

Table 1. Comparison between control and PRP group in wound's dimension

Week	Mean \pm SE		LSD value
	Control	Treated	
Week 1	7.30 ± 0.33	6.55 ± 0.30	0.943 NS
Week 2	5.78 ± 0.33	4.89 ± 0.33	0.984 NS
Week 3	4.84 ± 0.23	3.33 ± 0.48	1.142 *
Week 4	4.34 ± 0.36	1.87 ± 0.08	0.936 *
Week 5	3.85 ± 0.31	1.29 ± 0.11	0.807 *
Week 6	2.79 ± 0.29	0.811 ± 0.10	0.866 *
Week 7	2.24 ± 0.23	0.667 ± 0.12	0.713 *
LSD value	2.406 *	2.057 *	---

* ($P < 0.05$) Significant, NS: Non-Significant.

Second group (PRFM): In this group measurements of wounds dimensions showed no significant variation in first weeks between their control (6.87 ± 0.26) and treatment groups (5.98 ± 0.35). However showed significant variation ($P < 0.05$) in the second week in the treatment group (4.59 ± 0.36) in comparison with their control (5.77 ± 0.24), in which they lasted until the end of the study with

significant variation (2.54 ± 0.26) of control group (0.453 ± 0.02) and treatment group (0.453 ± 0.02) (Table 2).

The results of the PRP and PRF groups in measurement of wounds dimensions showed no significant variation between these groups along this study (Table 3).

Table 2. Comparison between control and PRF matrix group in wound's dimension

Week	Mean \pm SE		LSD value
	Control	Treated	
Week 1	6.87 ± 0.26	5.98 ± 0.35	0.914 NS
Week 2	5.77 ± 0.24	4.59 ± 0.36	0.916 *
Week 3	5.14 ± 0.22	2.89 ± 0.16	0.598 *
Week 4	4.06 ± 0.13	1.83 ± 0.16	0.476 *
Week 5	3.50 ± 0.16	1.32 ± 0.14	0.478 *
Week 6	3.12 ± 0.24	0.60 ± 0.02	0.669 *
Week 7	2.54 ± 0.26	0.453 ± 0.02	0.725 *
LSD value	1.984 *	2.297 *	---

* (P<0.05) Significant, NS: Non-Significant..

Table 3. Comparison between PRP and PRF groups in wound's dimension

Week	Mean \pm SE		LSD value
	PRP	PRF	
Week 1	6.55 ± 0.30	5.98 ± 0.35	0.831 NS
Week 2	4.89 ± 0.33	4.59 ± 0.36	0.605 NS
Week 3	3.33 ± 0.48	2.89 ± 0.16	0.724 NS
Week 4	1.87 ± 0.08	1.83 ± 0.16	0.522 NS
Week 5	1.29 ± 0.11	1.32 ± 0.14	0.578 NS
Week 6	0.811 ± 0.10	0.60 ± 0.02	0.496 NS
Week 7	0.667 ± 0.12	0.453 ± 0.02	0.561 NS
LSD value	2.297 *	2.297 *	---

* (P<0.05) Significant, NS: Non-Significant.

Biomechanical evaluation of wounded skin in this study showed an increase in tensile strength of both treated groups in compared to their control groups ($P \leq 0.05$), but these groups showed no significant variation ($P \geq 0.05$) in tensile strength when they compare between the PRP and PRF groups as in which table 4 (Figure 4).

Table 4. Tensile strength of wounded skin

The Group	Mean \pm SE of Tensile strength
Normal skin	83.50 ± 0.00
Control	11.05 ± 1.69
PRP	19.85 ± 2.71
PRF	16.97 ± 2.37
LSD value	4.083 *

* (P<0.05) Significant, NS: Non-Significant.

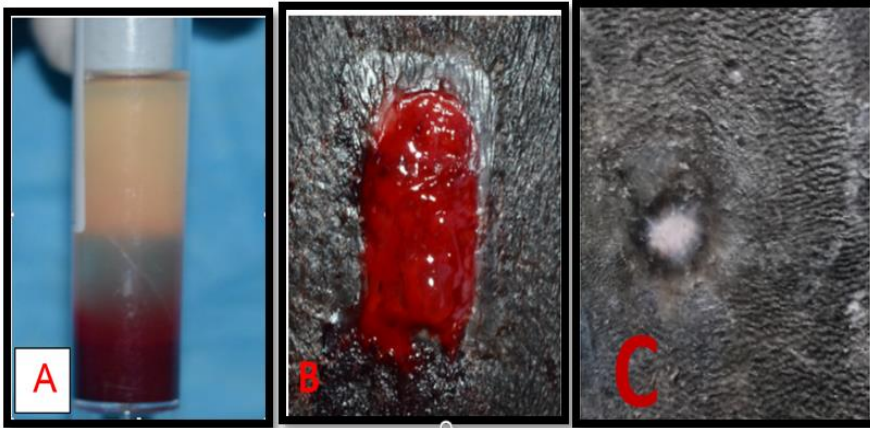


Figure 1. shows PRP preparation (A), at treatment time (B) and after 7 week after treatment (C)

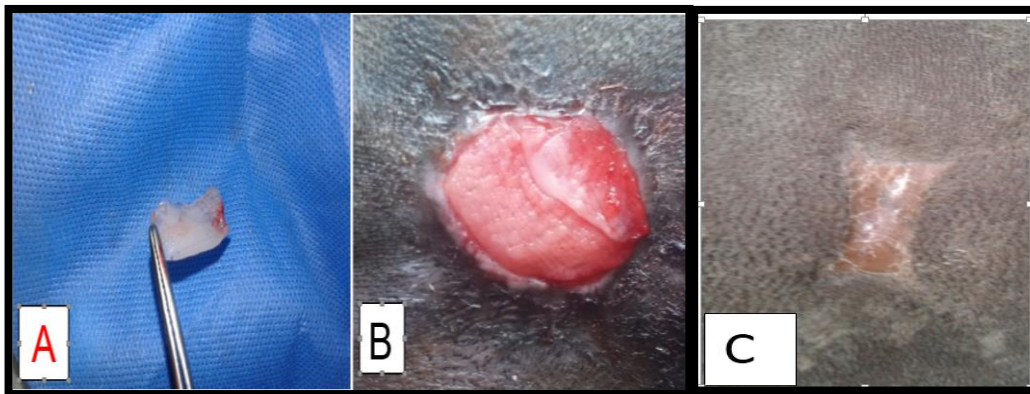


Figure 2. Shows PRF preparation (A), at treatment time (B) and after 7 week after treatment (C)

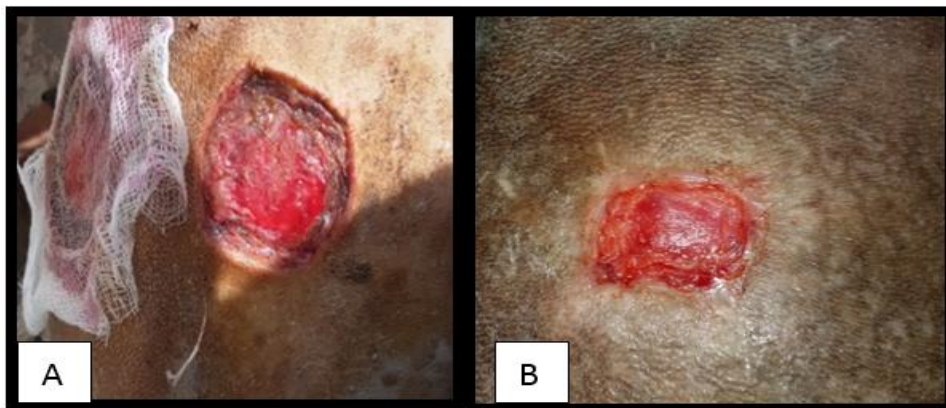


Figure 3. Shows chronic wounds induction through second weeks (A) and 8 week post inducing (B)

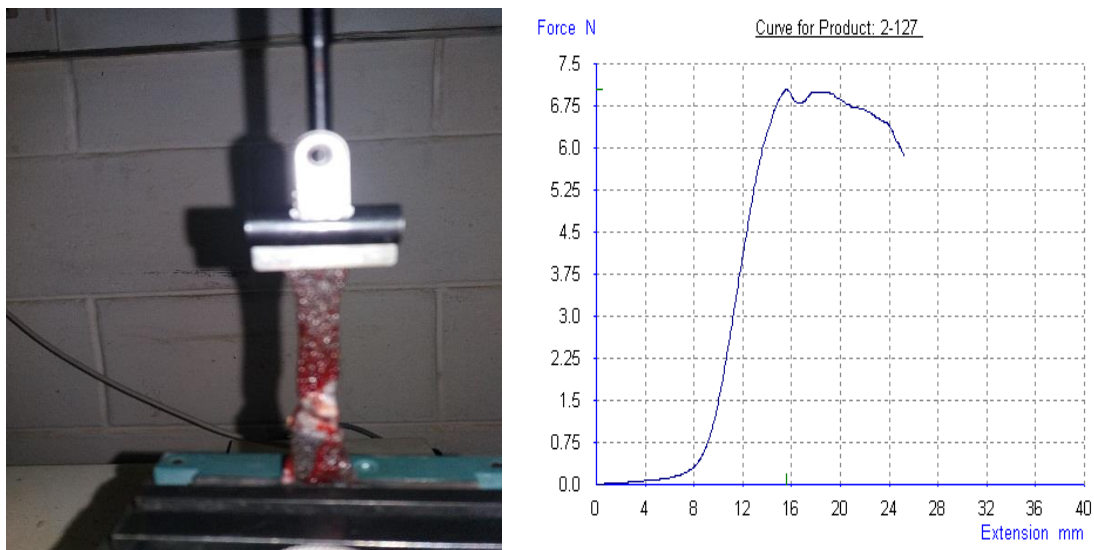


Figure 4. Shows tensometer apparatus: with tissue test and tensile strength measurement graphically

DISCUSSION

The chronic wounds were created and continuously irritated mechanically and left for eight weeks to emphasize their chronicity; this fact confers with other researchers who discussed the time of the possibility of inducing chronic stage in wound. Gürgen (2008) referred to the wound healing as a complex process which is regulated by interactions between a large number of cell types, extracellular matrix proteins and mediators such as cytokines and growth factors. Lack of balance between these interactions may result in a chronic wound. Fonder *et al.*, (2008) revealed that a chronic wound is the wound that takes 6 weeks or more in repair process to reflect chronic state of healing. Izadi and Ganchi (2005) also reported that wound that fails to progress through a normal sequence of repair in 4 to 8 weeks, is generally presumed to be chronic.

Clinical follow up in this period showed typical chronic wounds, without signs of infections or systemic reactions and these results were related to the aseptic technique and healthy housing of animals, but local symptoms related to normal tissues reacted toward traumatic, daily surgical irritation of wounds sites, which induce normal tissues reaction toward causative agents (Hom *et al.*, 2007; Young and Mcnaught, 2011).

In treated groups the platelets rich plasma gel and autologous of platelets rich fibrin matrix were used in treating of chronic cutaneous wounds in bucks, as cell therapy involving many bioactive factors. Therapeutic application may be achieved by simple techniques, effectiveness, easy preparation and applied to the

surgical site without using special equipment or device and this investigation were also proved by Jee *et al.*, (2016), DeRossi *et al.*, (2009) and Dohan *et al.*, (2006).

The results of PRP gel and PRF matrix application on experimental chronic open cutaneous wounds showed faster, safety, and augmentation healing process than their control groups. These characteristics reflect accelerated tissue regeneration, which is one of the known effects of PRP application (Fernandez-Moure *et al.*, 2017) and the use of PRF also represents a regenerating, enhancing, or replacing either damaged or missing tissues for a variety of conditions caused by trauma or disease and safety of using PRF, convenient, easy-to use adjuvant therapy with significant potential for closing chronic wounds without adverse events (Miron *et al.*, 2016 ; Pinto *et al.*, 2017).

In both treatment groups, wound measurements showed significant variations in wounds dimensions which started from the second week post operation, after second treatment, these results agree with Farghali *et al.*, (2017), who referred to significant values of treated wounds with PRP at second week post-surgery. Additionally Strukova *et al.*, (2001), found decreased wound dimensions as result of increased fibroblast in 60%, to macrophage ratio and increased proliferating fibroblasts. Furthermore more researchers focused on effects of PRP or PRF in tissues repair and wound healing such as Ostvar *et al.* (2016) who demonstrated that, PRP application gave significantly smaller wound dimensions compared to the non-treated groups in rabbits.

The result of PRP treated wound in this study disagreed with Mehrjerdi, *et al.*, (2008) who referred to the non significant difference in percentage of contraction, epithelialization and healing among wounds of control and test group in dogs. These results might be due to differences in PRP biology among species, variation in PRP preparation techniques and alternative in PRP activity (Plachokova *et al.*, 2009).

Raja and Naidu (2008) demonstrated that the PRF were applied directly into a lesion as a matrix for regeneration, as an immediate effect, and they found that PRF were provided more rapid hemostasis and tissue adhesion by forming a fibrin clot, similar to fibrin glue, application of PRF increases the physiologic response to a wound emulating and surpassing the “normal” deposition of growth factors and proteins in wound, increased tissue regeneration and a lower rate of infection, pain and blood loss, Alishahi *et al.*, (2013) also demonstrated that PRF may accelerated incisional wound healing in canine.

The obtained results of two PRP and PRF groups demonstrated that applying PRP and PRF matrix to chronic wound may result in a significant healing effect, without significant variation in between these groups in wounds dimensions during time of this study. The above result might be related to platelets role in wound healing in hemostasis and initiation of wound healing. After platelet activation and clot formation, growth factors are released from α -granules, furthermore, adenosine are also stored in these dense granules and these growth factors work as biologic mediators to promote cellular activity by binding specific cell surface receptors (Foster *et al.*, 2009 ; Fernandez-Moure *et al.*, 2017). This result agrees with Dutta *et al.*, (2016) found that no significant difference between PRP and PRF groups on soft tissue healing, and bone regeneration after mandibular third molar extraction in human patients.

Biomechanical assessment of wounded skin in this study indicated an increase in tensile strength of both treated groups in comparison to its control groups, and lesser than in unwounded skin and these results agreed with Chao *et al.*, (2013) who demonstrated that the limit displacement was smaller in healing skin wound tissues as compared with uninjured skin, also they referred that the stiffness value obtained on day 10 was the lowest (only 18.7% of the baseline unwounding status), which gradually regained to 58.72% on day 21. As compared to unwounded skin, the ultimate tensile force dropped markedly in the tissues of the healing wound, to 37.0% of the normal skin on day 3 and then recovered to 49.0% on day 21. The ultimate tensile stress of the wounds, as measured by the breaking force divided by the cross-sectional area of the skin specimen, declined significantly to 25.5% of the normal skin value on day 3 and then increased to 48.2% on day 21.

Tatar *et al.*, (2017) found that injection of PRP may increase statistically the tissue durability comparing to the other groups. The mechanical integrity and wound strength of the wound are determined by the quantity and quality of collagen and also referred that the accumulation of collagen in wound healing reaches a maximum value 2-3 weeks after the injury. Tensile strength gradually increased with the organized fibrils with more intermolecular bonds replacing the collagen fibers. There is a direct correlation between tensile strength and thickness of collagen fibrils and they also found that the results of the mechanical tensile tests were better in the injected group.

REFERENCE

- Al-Bayati, A. H., R. N. Al-Asadi, A. K. Mahdi and N. H. Al-Falahi. 2013. Effects of autologous platelets rich plasma on full-thickness cutaneous wounds healing in goats. *Int. J. Anim. Vet. Adv.* 5: 233-239.
- Alishahi, M. K., D. Kazemi, D. Mohajeri, H. Mofidpoor, A. A. Goli and M. K. Alishahi. 2013. Histopathological evaluation of the effect of platelet-rich fibrin on canine cutaneous incisional wound healing. *I. J. Vet. Scie. Tech.* 5(2): 19-32.
- Chao, C. Y. L., G. Y. F. Ng, K. Cheung, Y. Zheng, L. Wang and G. L. Y. Cheing. 2013. In Vivo and ex Vivo approaches to studying the biomechanical properties of healing wounds in rat skin. *J. Biomech. Engin.*, 135: 1-8.
- De Rossi, R., A. C. A. O. Coelho, G. S. De Mello, F. O. Frazílio, C. R. B. Leal, G. G. Facco and K. B. Brum. 2009. Effects of platelet-rich plasma gel on skin healing in surgical wound in horses. *Acta. Cir. Bras.* 24: 276-281.
- Dohan, D. M., J. Choukroun, A. Diss and S. L. Dohan. 2006. Platelet-rich fibrin (PRF): a second-generation platelet concentrate. Part I: technological concepts and evolution. *Oral. Surg. Oral Med. Oral Pathol. Oral Radiol. Endod.*, 101(3): 37-44.
- Dorothy, M., M. D. Adcock, D. C. Kressin, L. Ehrenfest, A. Richard and R. A. Marlar. 1997. Effect of 3.2% vs 3.8% sodium citrate concentration on routine coagulation testing. *A.J.C.P.* 107(1): 105-110.
- Dutta, S. R., D. Passi, P. Singh, S. Sharma, M. Singh and D. Srivastava. 2016. A randomized comparative prospective study of platelet rich plasma, platelet rich fibrin, and hydroxyapatite as a graft material for mandibular third molar extraction socket healing. *Nat. J. Maxillofac. Surg.* 7(1): 45-51.
- Farghali, H. A., N. A. Abd-El-Kader, M. S. Khattab and H. O. AbuBakr. 2017. Evaluation of subcutaneous infiltration of autologous platelet-rich plasma on skin-wound healing in dogs. *Bioscience Reports.* 37: 1-12.
- Fernandez-Moure, J. S., J. L. Van Eps, F. J. Cabrera, Z. Barbosa, G. M. del Rosal, B. K. Weiner, W. A. Ellsworth and N. Tasciotti. 2017. Platelet-rich plasma: a biomimetic approach to enhancement of surgical wound healing. *J. surg. Res.* 207: 33-44.
- Fonder, M. A., G. S. Lazarus, D. A. Cowan, B. Aronson-Cook, A. R. Kohli and A. J. Mamelak. 2008. Treating the chronic wound: A practical approach to the care of nonhealing wounds and wound care dressings. *J. Am. Acad. Dermatol.* 58(2): 185-206.

- Foster, T. E., B. L. Puskas, B. R. Mandelbaum, M. B. Gerhardt and S. A. Rodeo. 2009. Platelet-rich plasma: from basic science to clinical applications. *Am. J. Sports Med.* 37(11): 2259-2272.
- Frykberg, G. R. and J. Banks. 2015. Advances challenges in the treatment of chronic wounds. *Wound care*, 9(4): 560-582.
- Fufa, D., B. Shealy, M. Jacobson, S. Kevy and M. M. Murray. 2008. Activation of platelet-rich plasma using soluble type I collagen. *J. Oral Maxillofac. Surg.*, 66: 684-690.
- Gürgen, M. 2008. Treatment of chronic wounds with autologous platelet-rich plasma. *EWMA. J.* 8(2): 1-10.
- Hom, D. B., B. M. Linzie and T. C. Huang. 2007. The healing effects of autologous platelet gel on acute human skin wounds. *Arch. Facial Plast. Surg.* 9: 174-183.
- Izadi, K. and P. Ganchi. 2005. Chronic Wounds. *Clin. Plast. Surg.* 32: 209- 222.
- Jee, C. H., N. Eom, H. Hyo-Mi Jang, H. Jung, E. Choi, J. Won, I. Hong, B. Kang, D. W. Jeong, I. N. Dong, D. Jung. 2016. Effect of autologous platelet-rich plasma application on cutaneous wound healing in dogs. *J. Vet. Sci.* 17(1): 79-87.
- Jones, M. L. and R. W. Allison. 2007. Evaluation of the ruminant complete blood cell count. *Vet. Clin. North. Am. Food Animal Pract.*, 23(3): 377-402.
- Kim, J. H., C. Park and H. M. Park. 2009. Curative effect of autologous platelet-rich plasma on a large cutaneous lesion in a dog. *Vet. Dermatol.* 20: 123-126.
- Mehrjerdi, H. K., K. Sardari, M. R. Emami, A. R. Movassaghi, A. A. Goli, A. Lotfi and S. Malekzadeh. 2008. Efficacy of autologous platelet-rich plasma (PRP) activated by thromboplastin-D on the repair and regeneration of wounds in dogs. *Iran. J. Vet. Surg.* 3(4):19-30.
- Ostvar, O., S. Shadvar, E. Yahaghi, K. Azma, A. F. Fayyaz, K. Ahmadi and I. Nowrouzian. 2016. Effect of platelet-rich plasma on the healing of cutaneous defects exposed to acute to chronic wounds: a clinic-histopathologic study in rabbits. *Diag. Patho.* 11(113): 1-6.
- Perazzi, A., R. Busetto, T. Martinello, M. Michele Drigo, D. Pasotto, F. Francesco Cian, M. Patruno and I. Lacopetti. 2013. Description of a double centrifugation tube method for concentrating canine platelets. *BMC Vet. Res.* 9: 146.
- Pietrzak, W. S. and B. L. Eppley. 2005. Platelet rich plasma: biology and new technology, *Journal of Craniofacial Surgery*, 16(6): 1043-1054.

- Pinto, N. R., M. Ubilla, Y. Zamora, V. D. David, M. D. Ehrenfest and M. Quirynen. 2017. Leucocyte and platelet-rich fibrin (L-PRF) as a regenerative medicine strategy for the treatment of refractory leg ulcers: a prospective cohort study. *Platelets*, Early Online: 1-8.
- Plachokova, A. S., J. V. Dolder and J. J. P. Beucken. 2009. Bone regenerative properties of rat, goat and human platelet rich plasma. *Int. J. Oral Maxillofac. Surg.*, 38: 861-869.
- Raja, S. V. and M. E. Naidu. 2008. Platelet-rich fibrin: evolution of a second-generation platelet concentrate. *Indian J. Dent. Res.*, 19(1): 42-46.
- Robson, M. C., D. L. Steed and M. G. Franz. 2001. Wound healing: biologic features and approaches to maximize healing trajectories. *Curr. Probl. Surg.* 38: 72-140.
- Sardari, K., M. R. Emami, H. Kazemi, A. R. Movasagi, A. A. Goli, A. Lotfi and S. Malekzadeh. 2011. Effects of platelet-rich plasma (PRP) on cutaneous regeneration and wound healing in dogs treated with dexamethasone. *Comp. Clin. Pathol.* 20: 155–162.
- SAS. 2012. Statistical Analysis System, User's Guide. Statistical. Version 9th ed. SAS. Inst. Inc. Cary. N.C. USA.
- Shin, H., H. Woo and B. Kang. 2017. Optimization of a double-centrifugation method for preparation of canine platelet rich plasma. *BMC Vet. Research.* 13(198): 1-8.
- Simonpieri, A., M. Del Corso, A. Vervelle, R. Jimbo, F. Inchingolo and G. Sammartino. 2012. Current knowledge and perspectives for the use of platelet-rich plasma (PRP) and platelet-rich fibrin (PRF) in oral and maxillofacial surgery part 2: bone graft, implant and reconstructive surgery. *Curr. Pharm. Biotechnol.* 13: 1231-1256.
- Situm, M. and M. Kolić. 2012. Atypical wounds: definition and classification. *Acta. Med. Croatica.* 66(1): 5-11.
- Strukova, S. M., T. N. Dugina, I. V. Chistov, M. Lange, E. A. Markvicheva, S. Kuptsovas, V. P. Zubov and E. Iusa. 2001. Immobilized thrombin receptor agonist peptide accelerates wound healing in mice. *Clin. Appl. Thromb. Hemost.* 7: 325-329.
- Tatar, C., H. Aydin, T. Karsidag, S. Arikan, F. Kabukcuoglu, O. Dogan, A. Bekem, A. Unal and I. S. Tuzun. 2017. The effects of platelet-rich plasma on wound healing in rats. *Int. J. Clin. Exp. Med.*, 10(5): 7698-7706.
- Young, A. and C. Mcnaught. 2011. The physiology of wound healing. *Surg.* 29(10): 475-480.

دور هلام الصفائح الدموية الذاتي والليفين الغني بالصفائح الدموية في شفاء الجروح المزمنة في ذكور الماعز

سروه ابراهيم صالح²

فلاح حسن خلف^{3,1}

^{2,1} فرع الجراحة والتوليد- كلية الطب البيطري- جامعتي ديالى وبغداد على التوالي، العراق.

³المسؤول عن النشر: fhkhlaf@gmail.com

المستخلص

هدفت الدراسة إلى تقييم كفاءة استعمال هلام الصفائح الدموية الغني بالبلازما ومصفوفة الليفين الغني بالصفائح الدموية في تسريع التئام الجروح المزمنة المستحدثة في ذكور الماعز سريريا وتقييم التغيير الحيوي الميكانيكي لمنطقة الجرح.

اجريت الدراسة باستعمال 24 حيوان بالغ (بعمر 2-3 سنوات وبمعدل وزن 25-35 كغم) سليم ظاهريا، تم استحداث 4 جروح بمعدل قياس (4×4 سم) لكل جرح وبمسافة 10 سم بين كل جرحين في الجزء العلوي من الظهر وعلى الجانبين بازالة كامل التركيب النسيجي للجلد تحت تأثير المسدر الخفيف والتخدير الموضعي في حافات الجرح بعد تحضير المنطقة بتقنية التطهير الجراحي المعتمدة، احدها للمعالجة والاخر لمجموعة السيطرة، هذه الجروح تم تخريشها او تخديشها جراحيا يوميا لزيادة التفاعل الالتهابي وقطع عملية الشفاء الطبيعية للجرح ومنع تكوين النسيج الحبيبي في الجرح ولمدة 8 اسابيع لضمان ان هذه الجروح اصبحت مزمنة. بعد هذه المدة تمت عملية العلاج باستخدام هلام الصفائح الدموية الغني بالبلازما في المجموعة الاولى (12 حيوان) ومصفوفة الليفين الغني بالصفائح الدموية في المجموعة الثانية (12 حيوان)، وتم تحضير كل من هلام الصفائح الدموية الغني بالبلازما ومصفوفة الليفين الغني بالصفائح الدموية في وقت اجراء المعالجة الجراحية. قيمت عملية الشفاء للجروح المستحدثة في هذه الدراسة سريريا وبقياس ابعاد الجروح اسبوعيا لمجموعتي المعالجة بهلام الصفائح الدموية الغني بالبلازما ومصفوفة الليفين الغني بالصفائح الدموية ومجموعات السيطرة لها وبالفحص الحيوي الميكانيكي لقوة شد الجروح في فترة 45 يوما بعد المعالجة الجراحية.

تبين من معدل قياس ابعاد الجروح لكلا مجموعتي المعالجة وجود فرق معنوي مع مجموعة السيطرة التابعة لها ولا يوجد فرق معنوي بين المجموعتين، واطهرت نتائج الفحص الحيوي الميكانيكي لقوة شد الجروح للمجاميع المعالجة احصائيا وجود زيادة بقوة الشد مقارنة بمجموعة السيطرة لكل منها ولا فرق معنوي بين المجموعتين.

يستنتج من الدراسة، ان التخريش الميكانيكي المستمر لمنطقة الجرح يؤدي الى تأخر الشفاء وحصول حالة الجرح المزمن، وان تطبيق كلا تقنيتي هلام الصفائح الدموية الغني بالبلازما ومصفوفة الليفين الغني بالصفائح الدموية في علاج الجروح المزمنة يساعد في تحسين عملية شفاء الجروح من دون اثار جانبية، وكلتا التقنيتين اعطت نتائج متقاربة وان الاختبار الحيوي الميكانيكي يعطي مؤشرا مهما لتقييم عملية شفاء الجروح.

الكلمات المفتاحية: الجرح المزمن، البلازما الغنية بالصفائح الدموية، المادة الأساس الفيبرين الغنية بالصفائح الدموية.